The Shoulder

Thomas Souza, DC

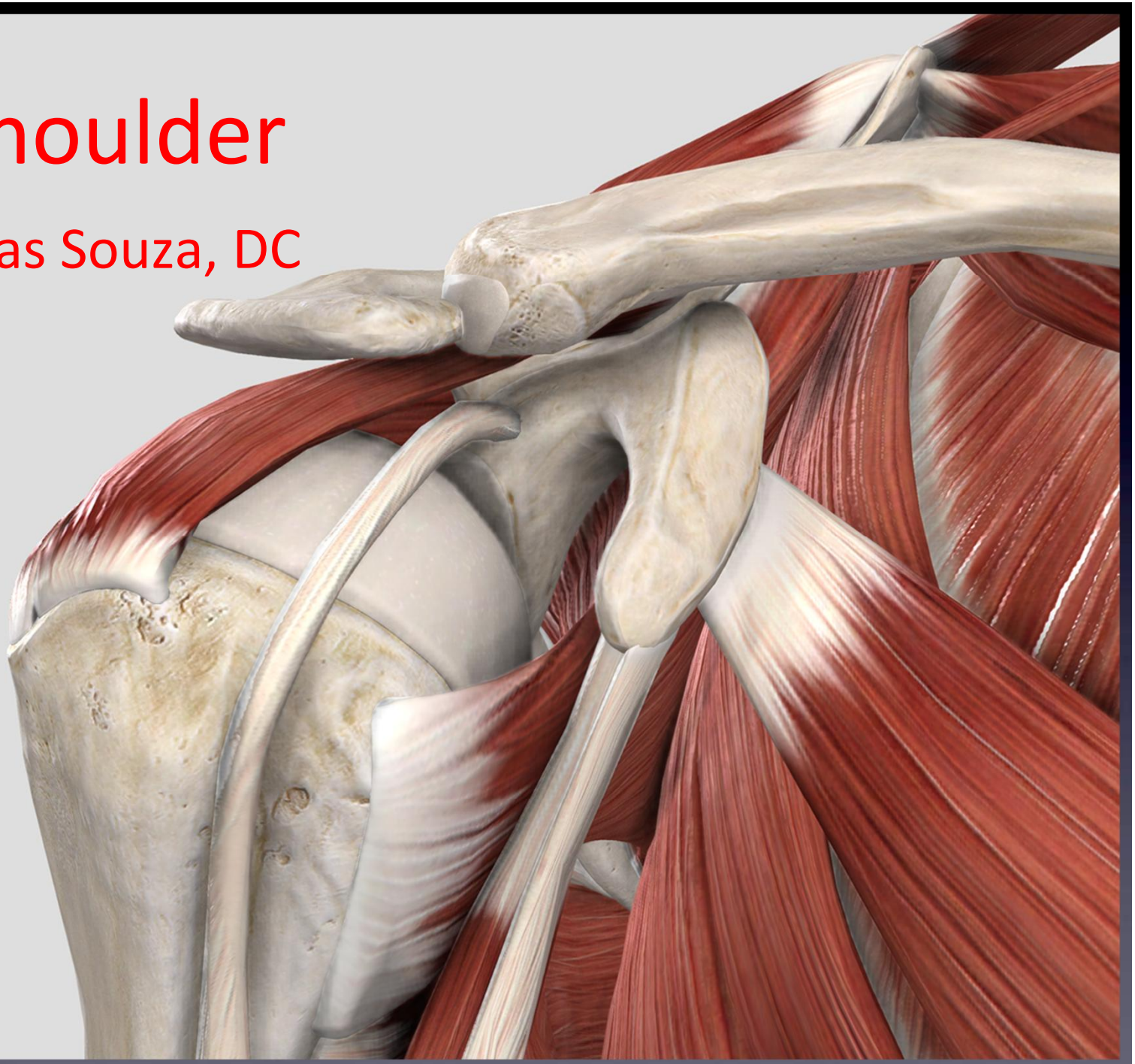

App Store Preview

This app is only available on the App Store for iOS devices.

Complete Anatomy 2019

12+

Professional 3D Human Atlas

3D4Medical.com, LLC

4.7, 2.3K Ratings

Free · Offers In-App Purchases

iPad Screenshots

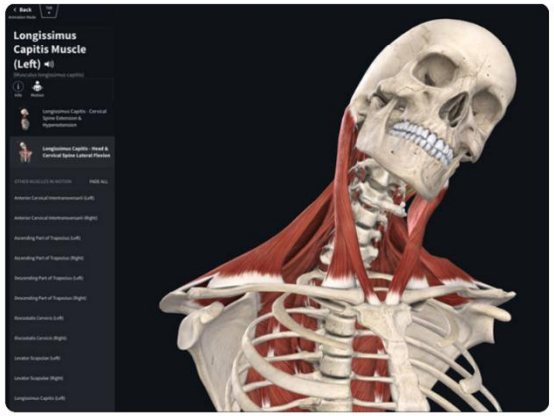

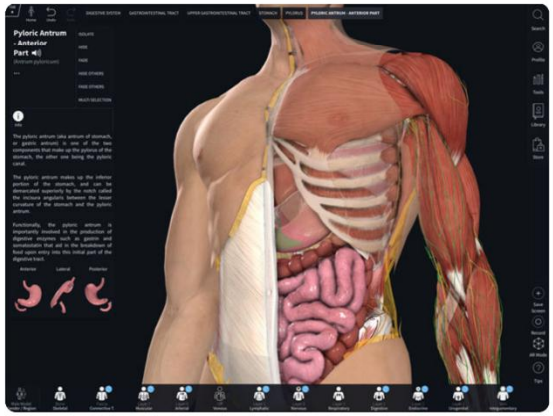

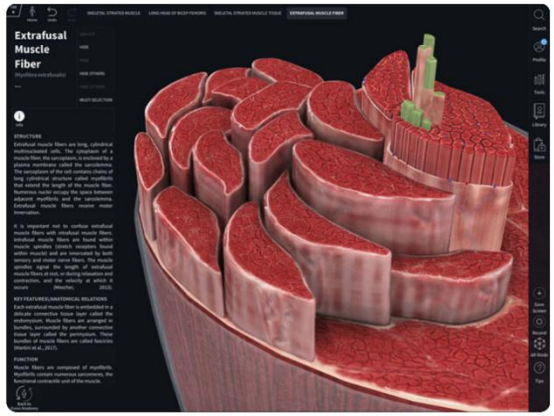

Photos

Context

Shoulder pain in the general population has been reported as high as 50% in some countries

Van der Heijden GJ. Shoulder disorders: a state-of-the-art review. *Ballieres Clin Rheumatol.* 1999;2:287-30

Luime JJ, Koes BW, Hendriksen IJ, et al. Prevalence and incidence of shoulder pain in the general population; a systematic review. *Scand J Rheumatol.* Vol 33; 2004:73-81.

Chronic shoulder pain appears to be common:

At 6 months following initial evaluation **34% to 79%** of patients report still having shoulder symptoms ; **24% to 61%** report pain *6 to 18 months* beyond the initial 6 month follow-up

Shoulder pain, like low back pain, is being recognized as an enigmatic complaint in that the source of pain and location of pain are not logically manifested as standard clinical presentations

This ambiguity is likely a reflection of the co-existence of many conditions (e.g. instability and labrum tears or impingement and rotator cuff tears) but also reflects the diagnostic difficulty of pinpointing the pain source

Risk of Shoulder Pain

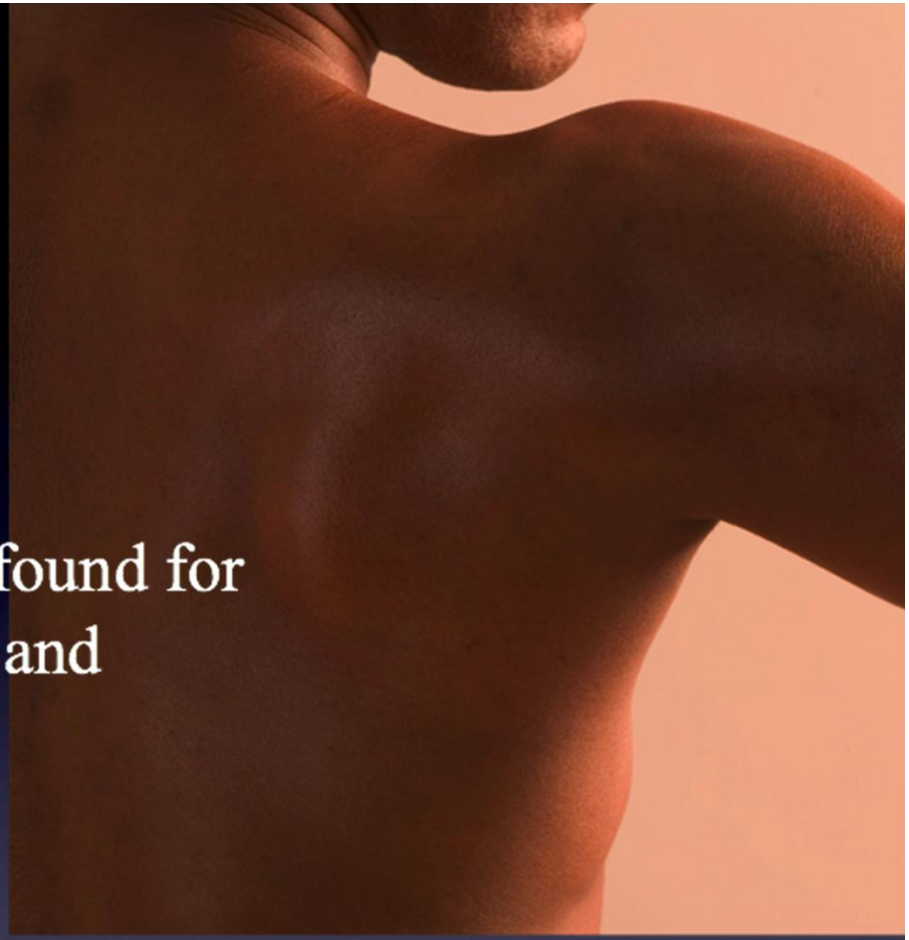

- Miranda et al. - an association found for increased risk of shoulder pain and
  - mental stress
  - obesity
  - older age
  - as well as physically strenuous work and working with the trunk forward flexed or with the hand above the shoulder level

Miranda H, Viikari-Juntura E, Martikainen R, Takala EP, Riihimaki H. A prospective study of work related factors and physical exercise as predictors of shoulder pain. *Occup Environ Med.* Aug 2001;58(8):528-534.

Leclerc et al., after adjustment for other risk factors, found that the presence of depressive symptoms was able to predict occurrence of shoulder pain.

There was an association between a low-level of job control and shoulder pain.

Leclerc A, Chastang JF, Niedhammer I, Landre MF, Roquelaure Y. Incidence of shoulder pain in repetitive work. *Occup Environ Med.* January 1, 2004 2004;61(1): 39-44.

Prognosis?

A prognostic study by Thomas et al. (2005) indicated that baseline characteristics *rather than treatment rendered* were a better predictor of outcome

(Quality Rating = 77)

Thomas E, van der Windt DA, Hay EM, et al. Two pragmatic trials of treatment for shoulder disorders in primary care: generalisability, course, and prognostic indicators. *Ann Rheum Dis.* Jul 2005;64(7):1056-1061.

Each of the following independently reduced the likelihood of recovery

- Being female
- reporting a gradual onset of shoulder pain
- having a higher baseline disability

Thomas E, van der Windt DA, Hay EM, et al. Two pragmatic trials of treatment for shoulder disorders in primary care: generalisability, course, and prognostic indicators. *Ann Rheum Dis.* Jul 2005;64(7):1056-1061

Instability	• Dislocation • Fracture • Labrum Tear • Atraumatic Looseness
Impingement	• Subacromial • Posterior • Tendinitis • GH Subluxation
Rotator Cuff Tears/Tendinitis	• Partial Tears • Full Tears • Tendinitis/Tendinosis • Bursitis
AC Disorders	• Separation - 3 Major (Common) Degrees • AC Osteoarthritis • AC Subluxation • Osteolysis
Capsulitis/OA	• Adhesive Capsulitis • Osteoarthritis • Other Arthritides

As a unifying principle, many shoulder problems can be linked directly or indirectly to *instability*

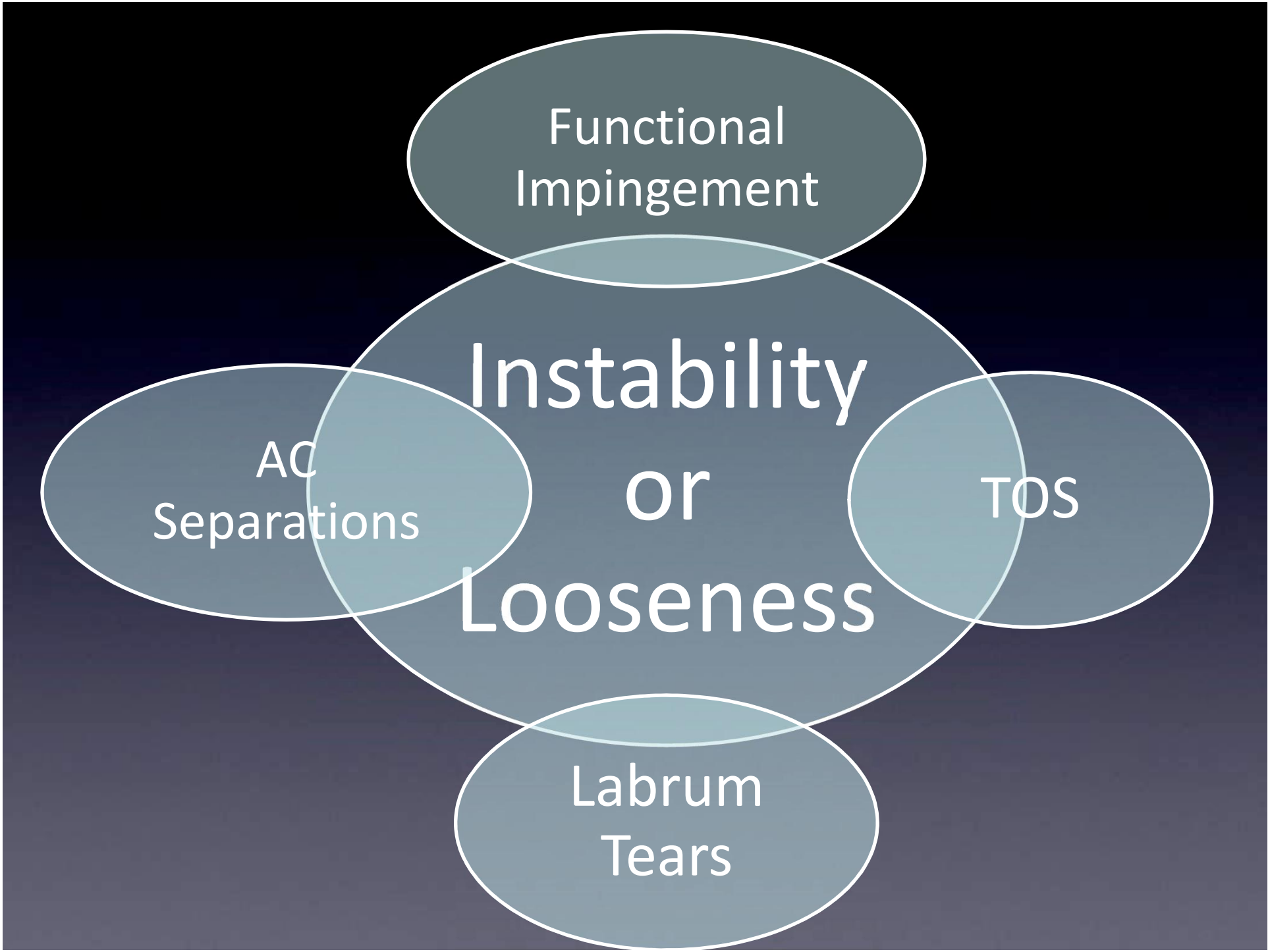
Functional Impingement
Instability or Looseness
AC Separations
TOS
Labrum Tears

OR

Born
Loose
AMBRI

Weak collagen leading to bilateral, multi-directional looseness

Torn
Loose
TUBS

Trauma leading to capsular tearing and possible labrum damage

Lagacha et al.

- At time of entry into the primary author's office (orthopedist): 87% of patients were unable to sleep on the affected side and 71% were unable to wash the back of the opposite shoulder.
- Those with instability seemed to present to a specialist around age 20-35 years.
- Patients with full-thickness tears present 15 years later than those with partial cuff tears.
- Those individuals with cuff tear arthropathy presented 13 years later than full-thickness tears.
- The conditions with greatest female prevalence were RA and adhesive capsulitis. All other conditions were male predominant

Largacha M, Parsons IMt, Campbell B, Titelman RM, Smith KL, Matsen F, 3rd. Deficits in shoulder function and general health associated with sixteen common shoulder diagnoses: a study of 2674 patients. *J Shoulder Elbow Surg.* Jan-Feb 2006;15(1):30-39.

Conditions Related to Age

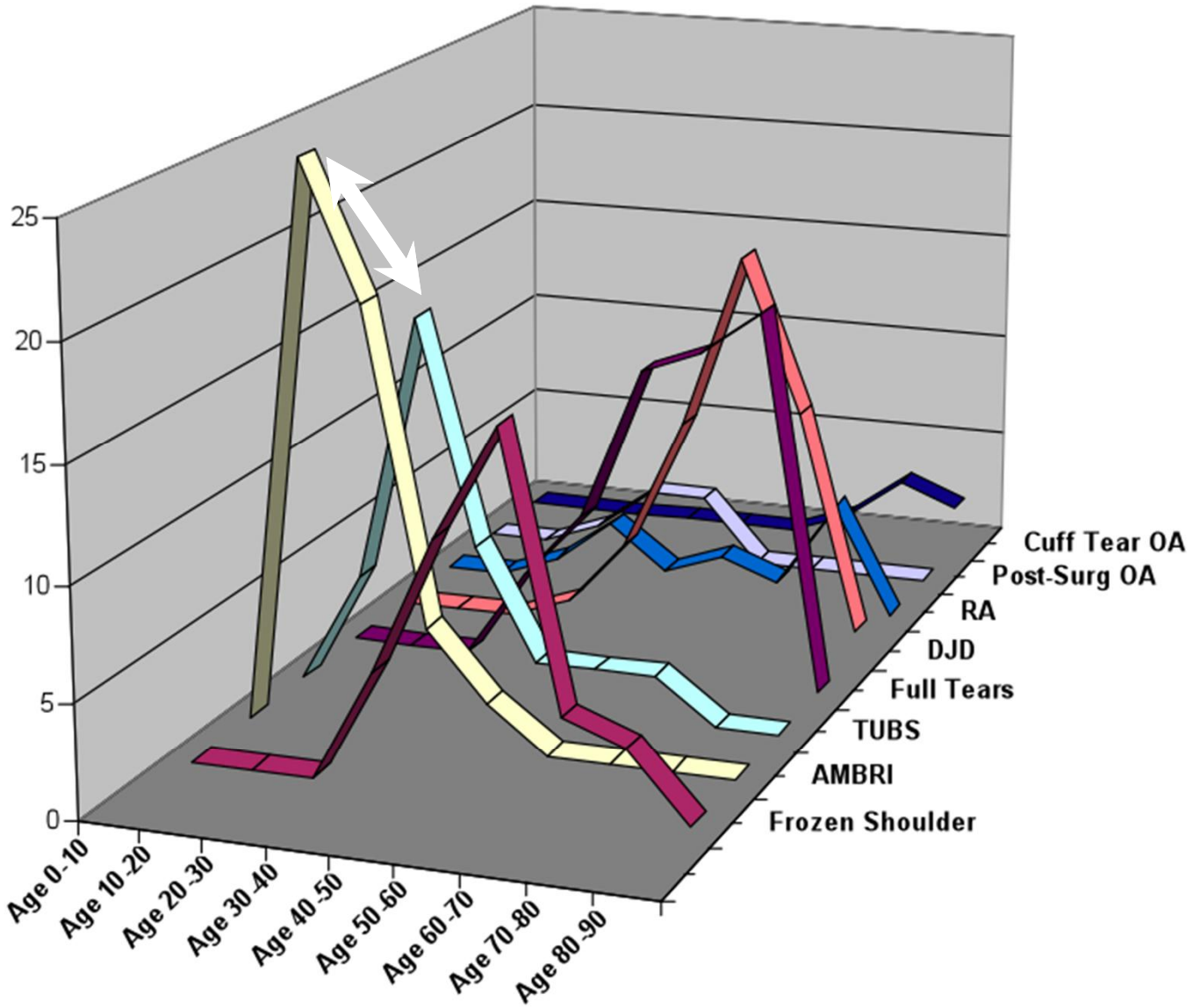

Common Mistakes in Evaluating the Shoulder

The History

Potential location of pain mistakes:

Pain vs. tenderness

"Shoulder" pain is shoulder pain

Location of pain often does not involved structure

Radiation is not always radicular

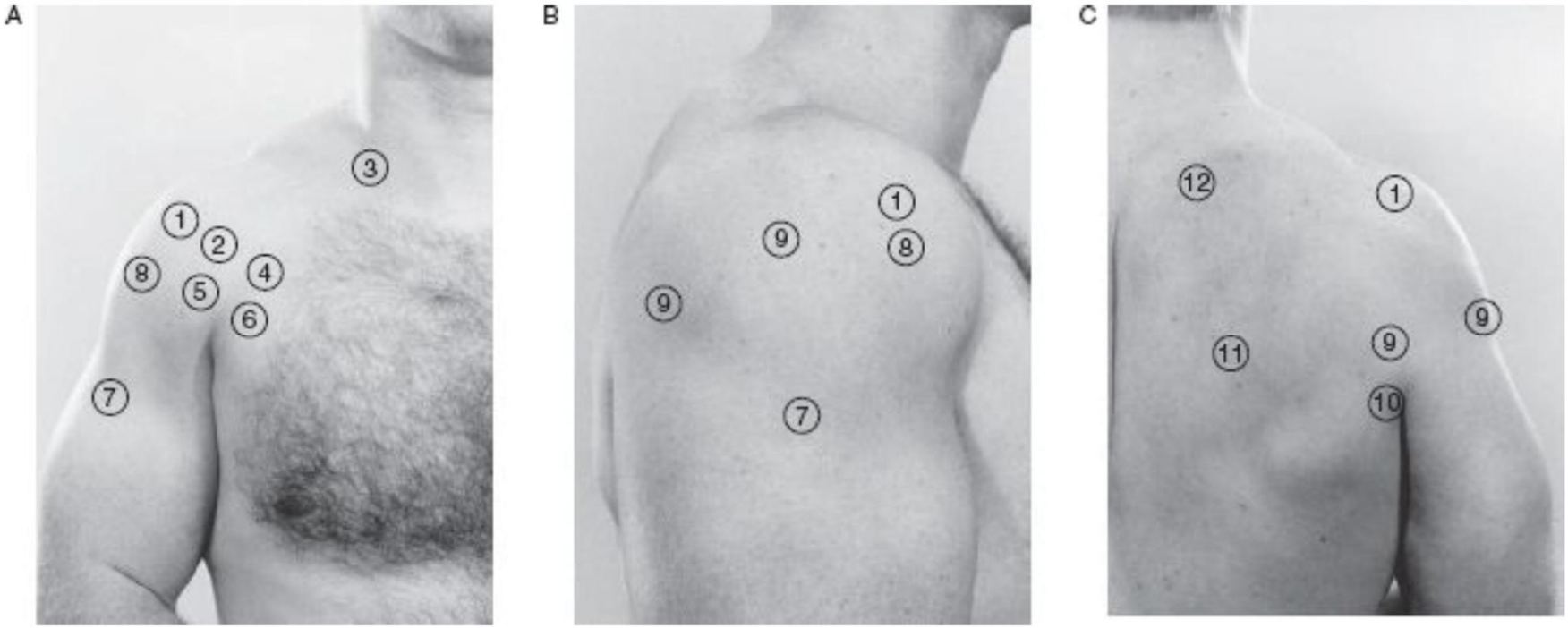
A
1
2
3
4
5
6
7
8
B
1
7
8
9
9
C
1
9
9
10
11
12

Palpation for ***Tenderness*** (not areas of pain)

- Infraspinatus/ Teres Minor (upper right)
- Supraspinatus (upper left)
- Biceps and Anterior Capsule (bottom)

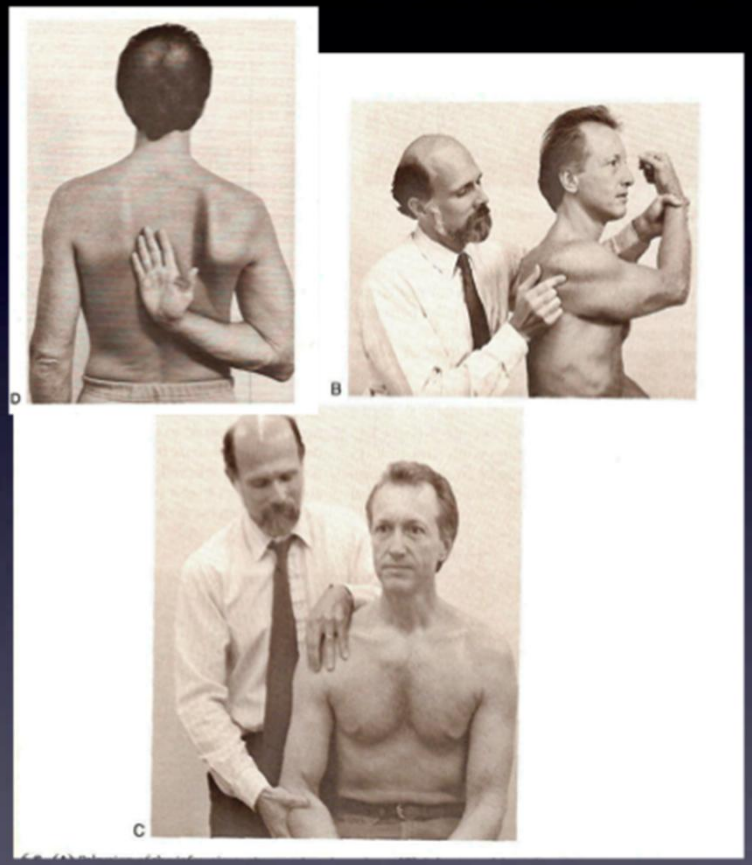

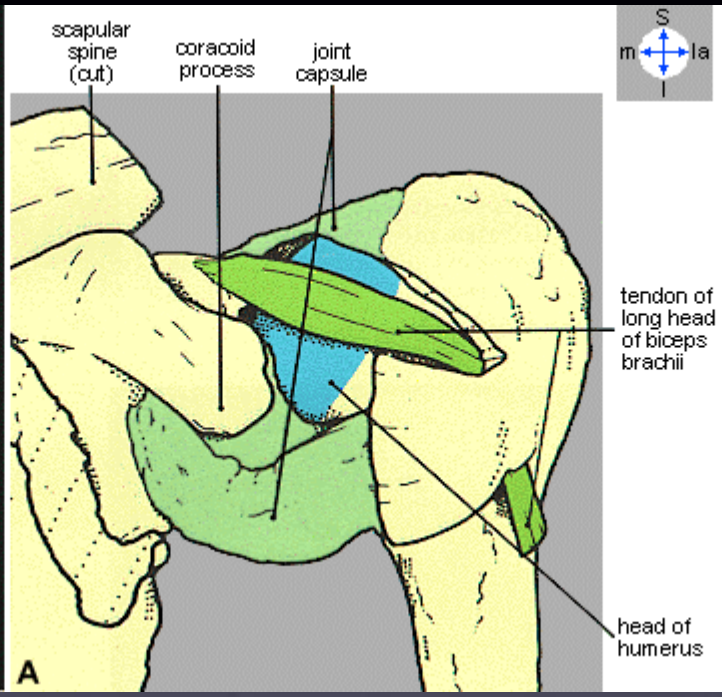
scapular spine (cut)
coracoid process
joint capsule
S
m
la
I
tendon of long head of biceps brachii
head of humerus
A

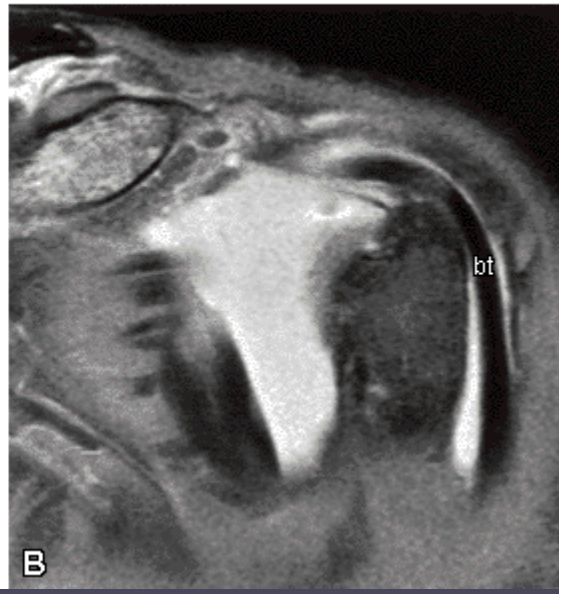
bt
B

Diagnoses You Don't Want to Miss

A 25-year old male patient presents with acute right shoulder pain.

He awoke with it this morning.

He can’t remember any trauma or unusual activity.

He has never had this before.

All shoulder movement is painful allowing only a few degrees in any direction.

His shoulder is also quite sensitive to touch.

A 55-year old male patient presents with left shoulder pain.

He awoke three weeks ago with severe pain unable to move his shoulder without a dramatic increase in pain.

He can’t remember any trauma or unusual activity. He has never had this before.

All shoulder movement is less painful compared to the initial onset allowing some movement but end-range pain; still a 6/10 with movement.

Differential Diagnosis

- Acute calcific bursitis/tendinitis
- Early adhesive capsulitis
- Brachial Neuritis (Parsonage-Turner syndrome)
- Rotator Cuff Tear

Calcific Tendinitis

An asymptomatic process of calcium deposition occurs first. Symptoms appear suddenly with the body's attempt to reabsorb the calcium by creating an acute inflammatory (rheumatoid-like) process

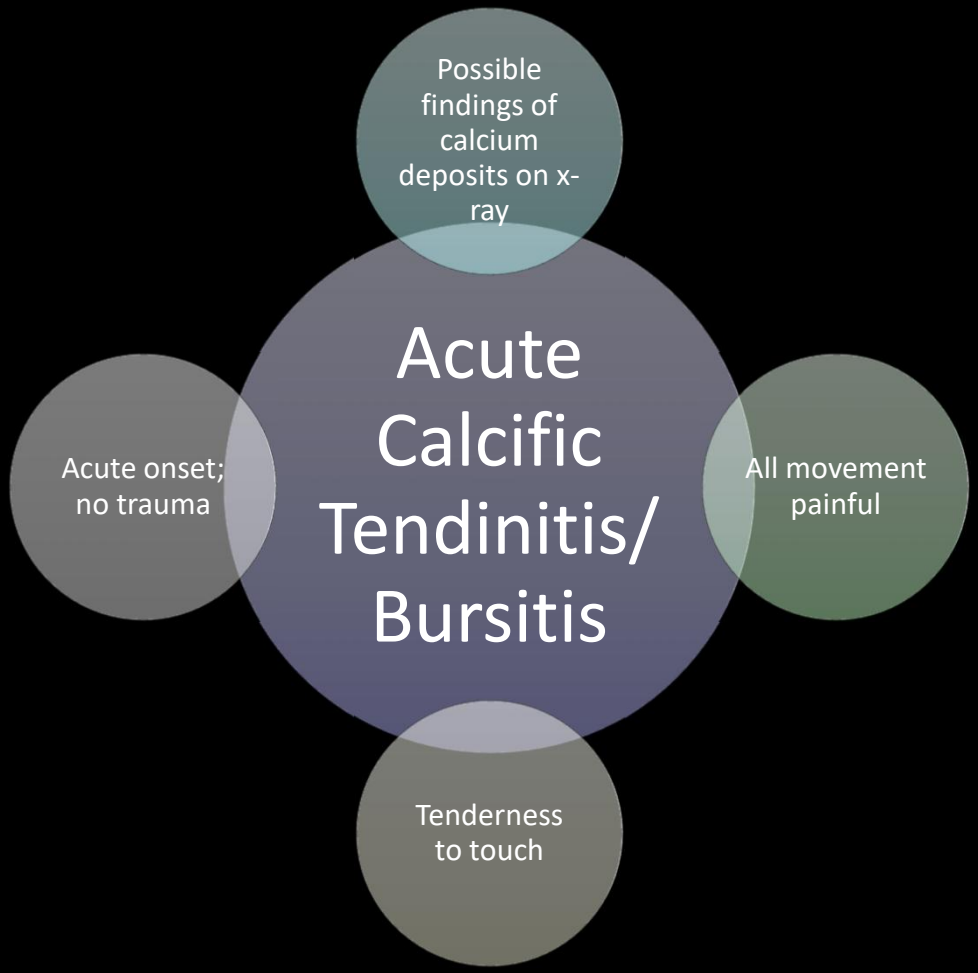

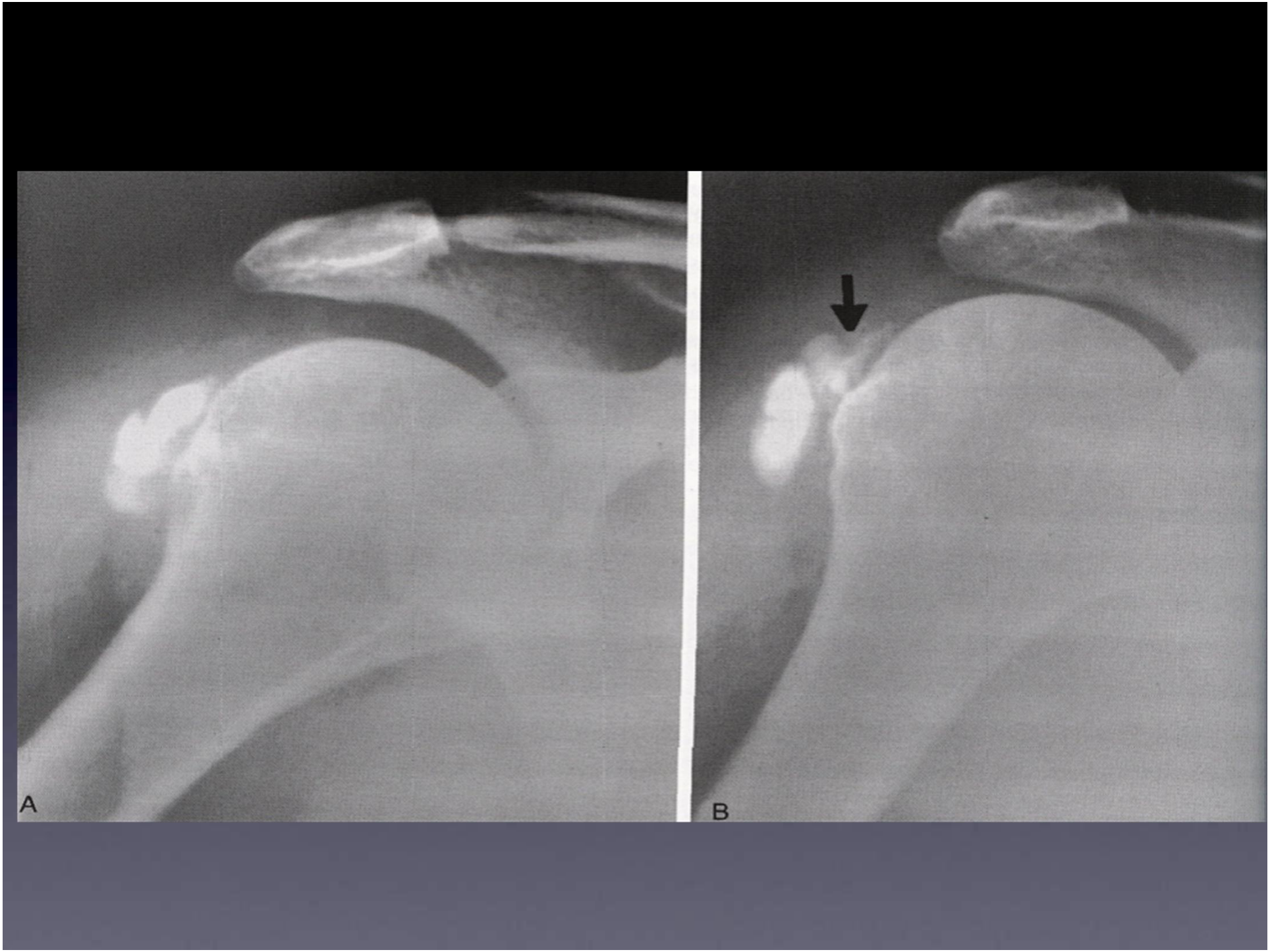
A
B

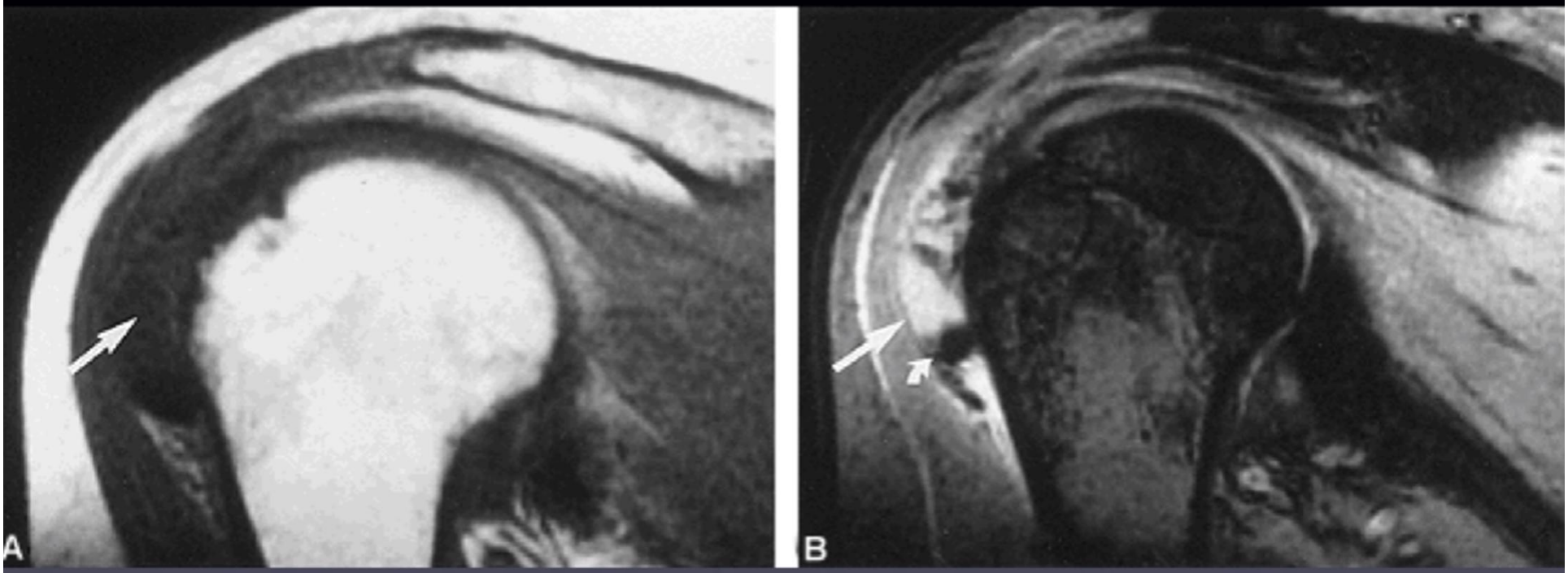
A
B

Ultrasound & Calicific Tendonitis

Ebenbichler et al. consecutive patients with a diagnosis of calcific tendonitis, (type 1 and 2) were randomized either to US or sham US. US consisted of **twenty-four, 15 minute sessions of pulsed US**

(frequency 0.89 mHz, intensity 2.5 W per square centimeter, *pulsed mode 1:4*)

(Quality Rating = 89)

Ebenbichler GR, Erdogmus CB, Resch KL, et al. Ultrasound therapy for calcific tendinitis of the shoulder. *N Engl J Med.* May 20 1999;340(20):1533-1538.

Extracorporeal Shock Wave Therapy (ECST)

Rompe JD, Burger R, Hopf C, Eysel P. Shoulder function after extracorporal shock wave therapy for calcific tendonitis. *J Shoulder Elbow Surg.* 1998;7:505–509

- Researchers in one study evaluated the difference between two protocols, one using a low-energy density (1500 impulses of 0.06 mJ/mm2 compared to 1500 impulses of 0.28 mJ/mm2, requiring the use of local anesthesia.
- Sixty-eight percent of patients in the high-intensity group rated the results of treatment good or excellent compared to only 52% in the low-energy group at a 6-month follow-up

Ioppolo F, Tattoli M, Di Sante L, et al. Extracorporeal shock-wave therapy for supraspinatus calcifying tendinitis: a randomized clinical trial comparing two different energy levels. *Phys Ther.* 2012;92(11):1376-1385

- In a small randomized trial, groups were also assigned to different energy levels.
- One group received ESWT at an energy level of 0.20 mJ/mm2, and the other group received ESWT at an energy levelof 0.10 mJ/mm2. Both groups received 2,400 pulses once a week for 4 weeks.
- Athough, calcific deposits resolved in the same percentage of patients in both groups. an energy level of 0.20 mJ/mm2 appeared to be more effective than an energy level of 0.10 mJ/mm2 if matched to the outcomes of pain relief and functional improvement again supported the previous study's findings.

Parsonage-Tuner Syndrome

Usually follows a viral infection with severe pain improving in 1-2 weeks but with residual neurologic damage

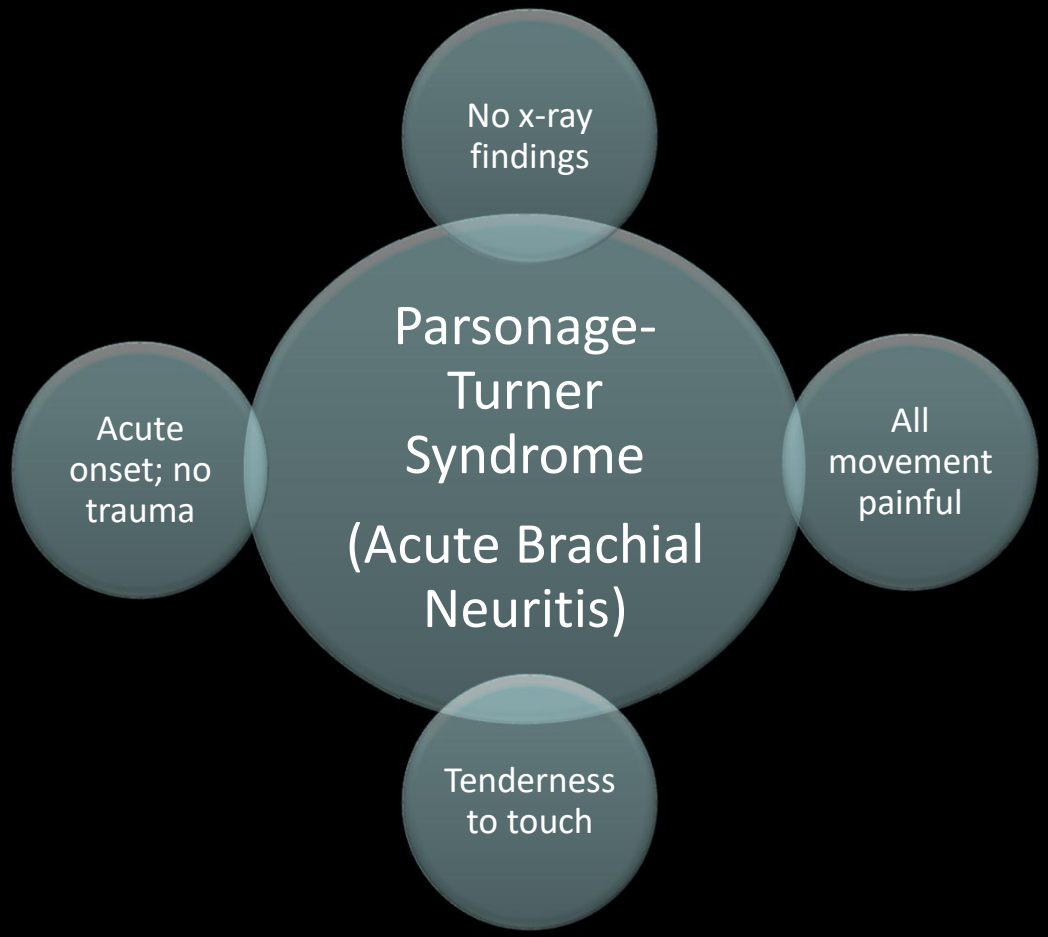

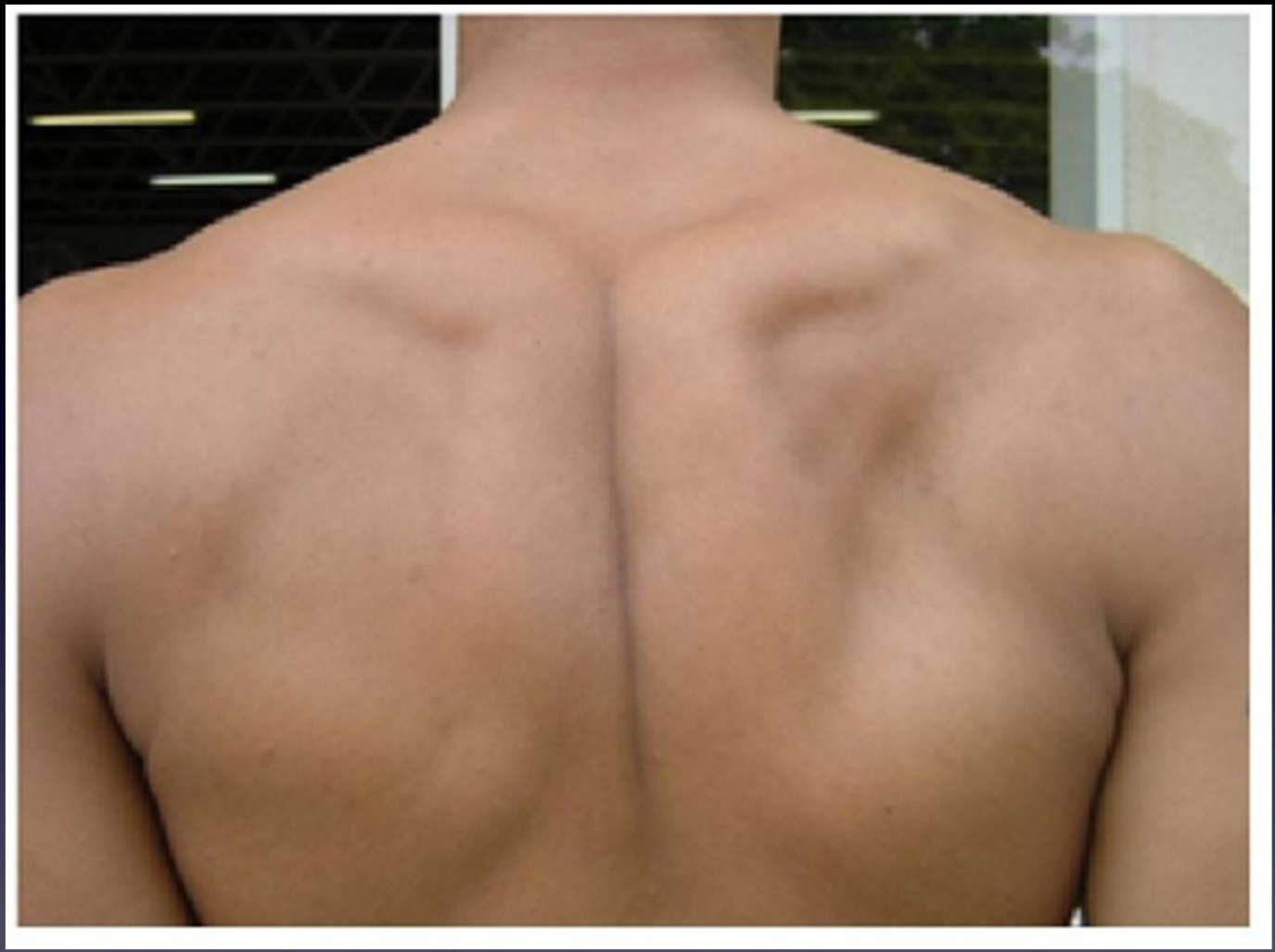

Electrophysiological correlates of the threshold to detection of passive motion: an investigation in professional volleyball athletes with and without atrophy of the infraspinatus muscle.

Salles JI, Cossich VR, Amaral MV, Monteiro MT, Cagy M, Motta G, Velasques B, Piedade R, Ribeiro P - Biomed Res Int (2013)

Adhesive Capsulitis

An acute inflammatory (rheumatoid-like) process that leads to capsular scarring and joint fibrosis

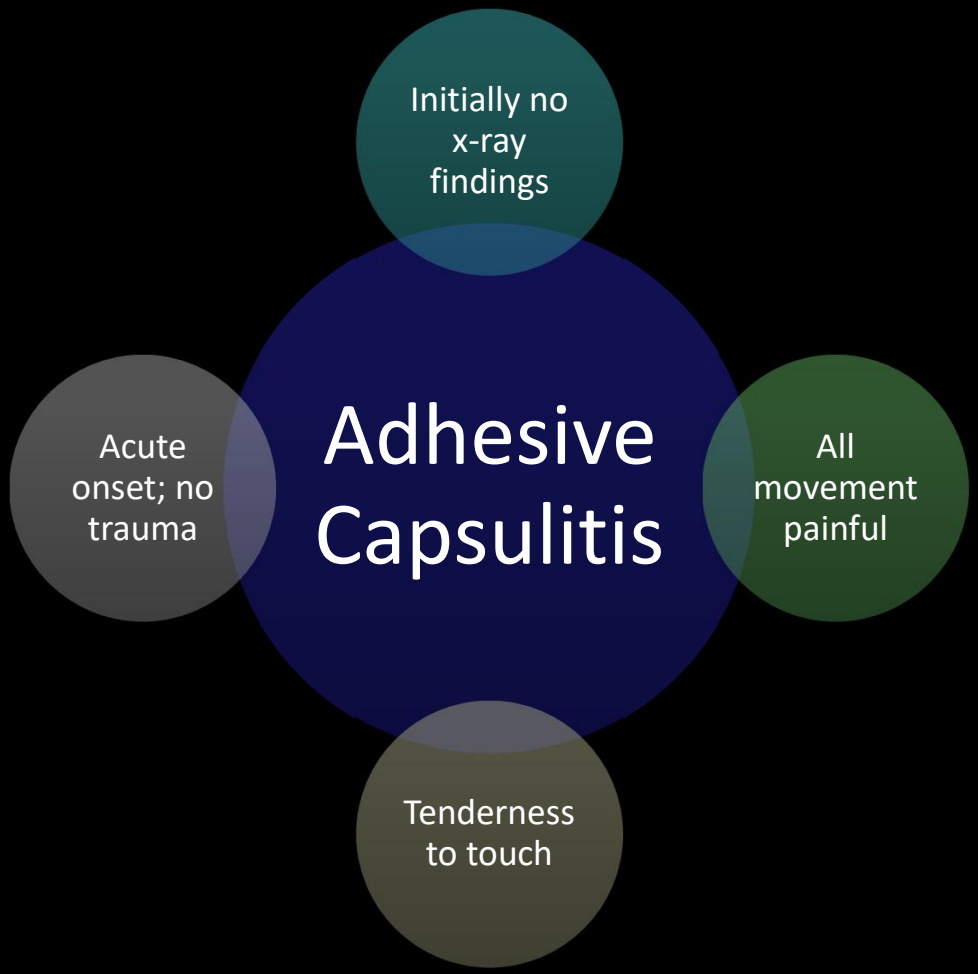

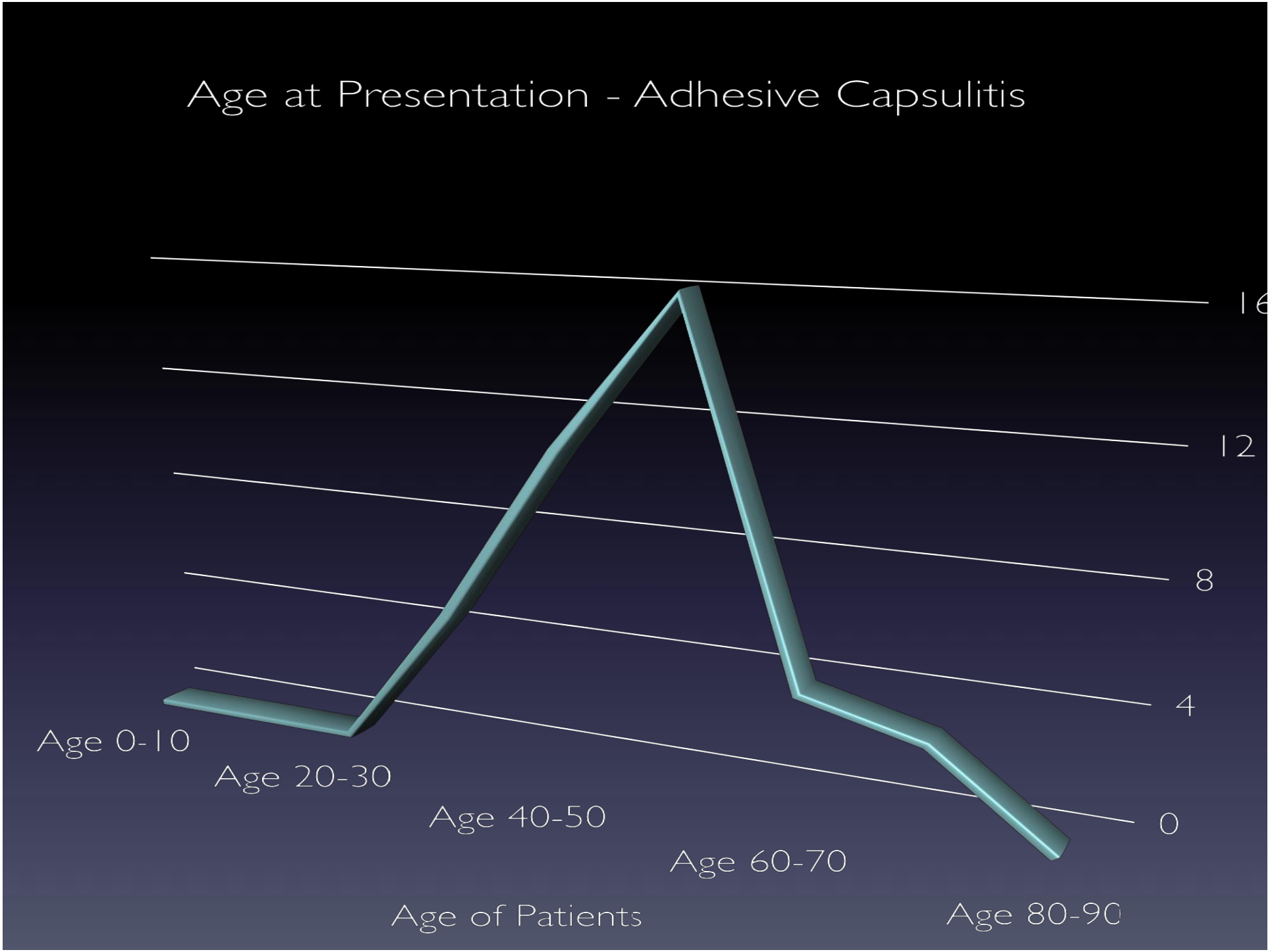
Age at Presentation - Adhesive Capsulitis
16
12
8
4
0
Age 0-10
Age 20-30
Age 40-50
Age 60-70
Age 80-90
Age of Patients

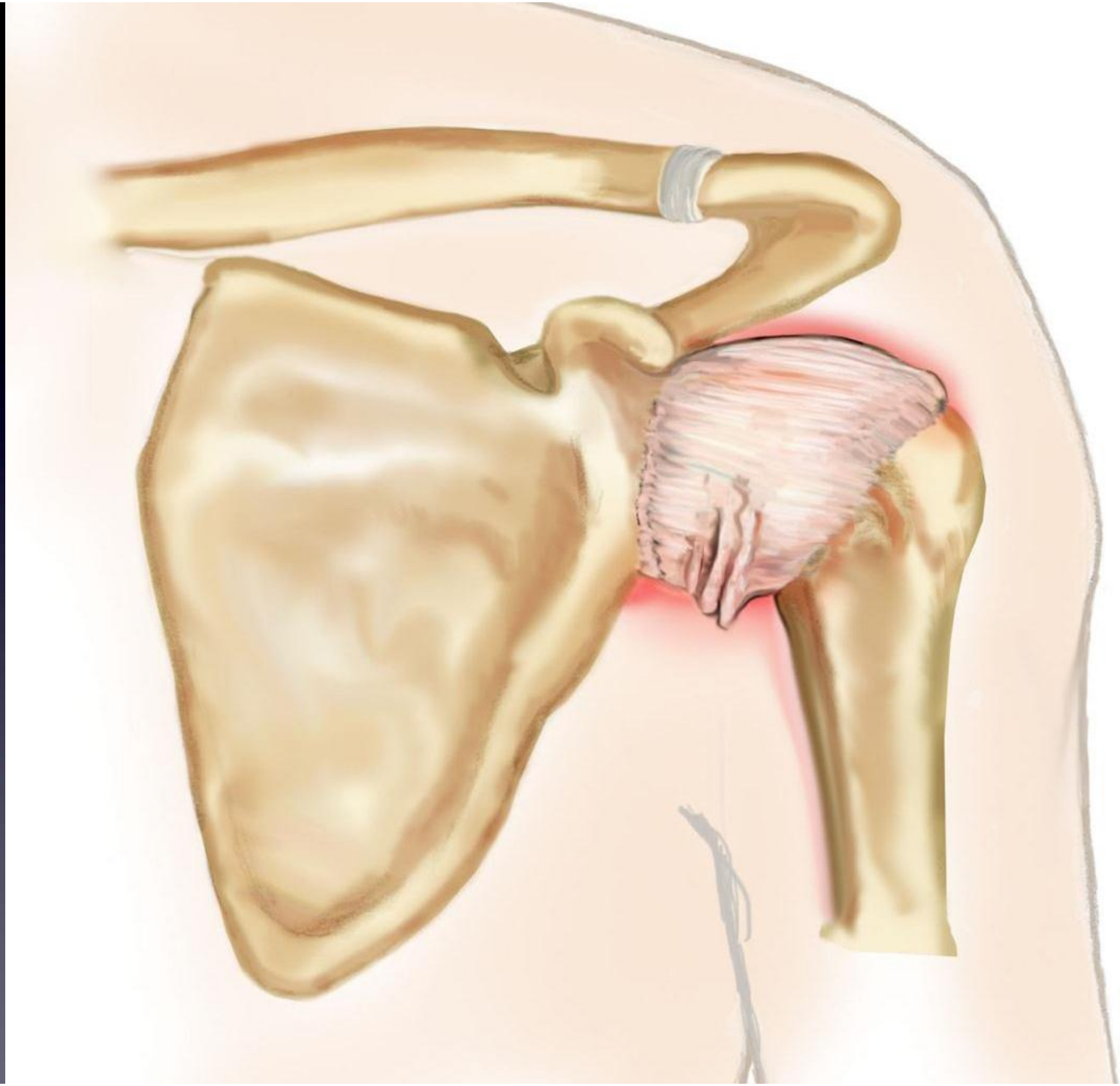


Severe Pain
Stiffness
Thawing
I Month
2-6 Months
12-18 Months

Adhesive Capsulitis Clinical Evaluation

Eventually, over a one month period, equal limitation in BOTH active and passive abduction and external rotation

Pendulum Exercises (Codman's)



Wall-Walking

(let your fingers to the walking)



Rotator Cuff Tears:

It’s Not What You Think!

For r***otator cuff tears:***

The combination of:

the history of a patient ≥ 65 suffering from night pain with weak external rotation

is helpful in ruling-in rotator cuff tear **if all** are positive; if none are positive, good at ruling-out rotator cuff tear

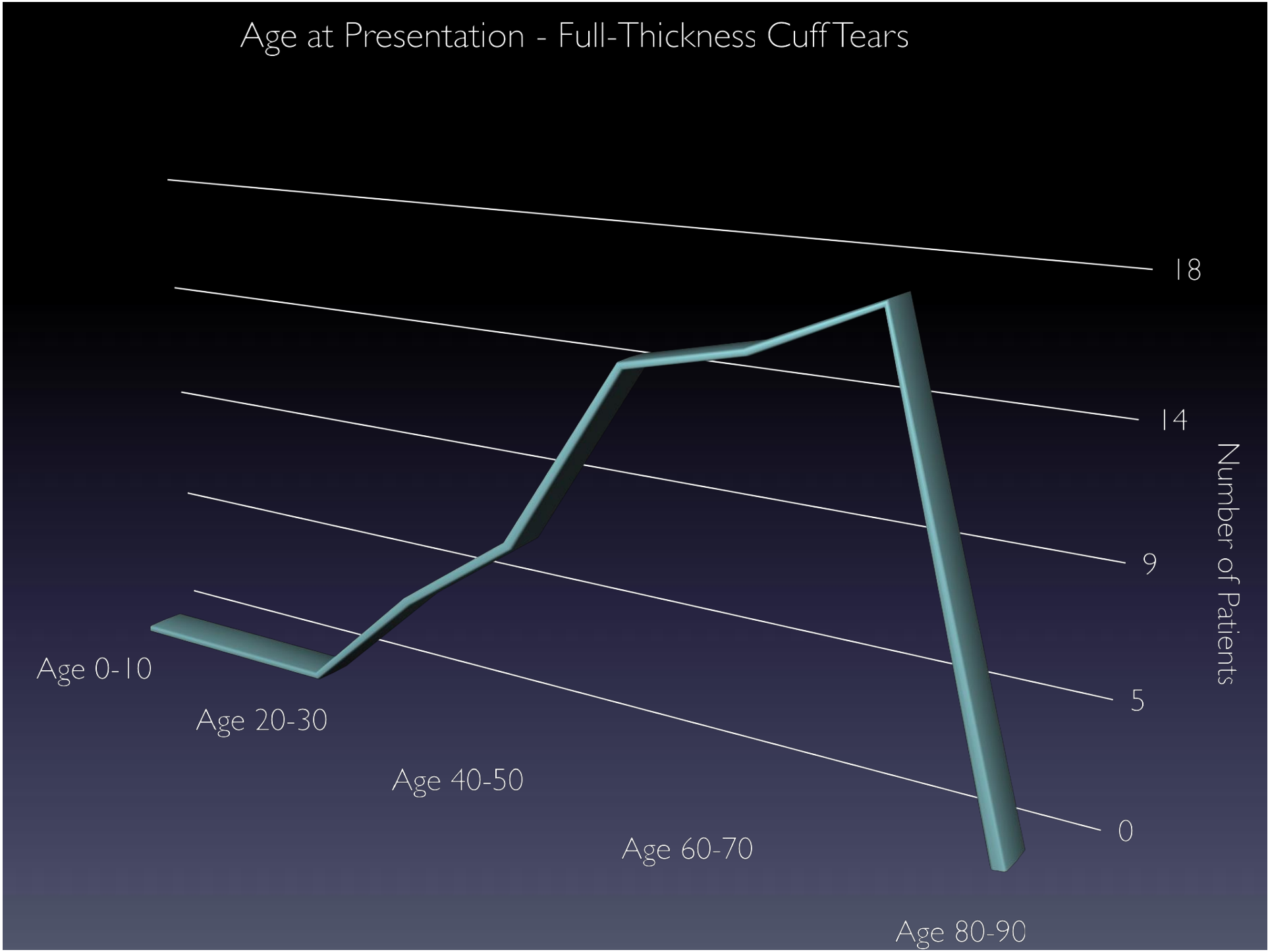
Age at Presentation - Full-Thickness Cuff Tears
18
14
9
5
0
Number of Patients
Age 0-10
Age 20-30
Age 40-50
Age 60-70
Age 80-90

The combination of the painful arc, drop-arm sign, and infraspinatus muscle test produced the best post-test probability (95%) for a full-thickness rotator cuff tear

Specific tests may identify some specific muscles if there is a full-thickness tear:

Subscapularis – the lift-off test, Internal Rotation lLg-Sign are good for ruling-in a full-thickness tear

Infraspinatus - infrapsinatus muscle test is reasonably good at ruling in a full-thickness tear. The External Rotation Lag Sign is a good rule-in and rule-out test for full-thickness tears

Supraspinatus – the drop-arm test is good rule-in and rule-out test for full thickness tears

Subscapularis

Internal Rotation Lag Sign

Lift-Off Test

External Rotation Lag Sign

Infraspinatus Full-Thickness Tear

A 55 year-old female has just had a MVA three days ago and reports extreme pain in her right shoulder.

She was the driver and was holding the steering wheel with her elbows locked into extension when she impacted the car in front of her.

There were standard AP internal and external views of the shoulder taken at the hospital.

She was told there were no visible fractures

An 18 year-old male bicyclist presents after a fall off of his bicycle.

He landed on an outstretched arm onto his right hand (palm hitting the road).

He is grabbing his shoulder saying that he hasn’t been able to move it without significant pain.

He hasn’t been able to take off his shirt, so it is difficult to determine any deformity

Differential Diagnosis

- Dislocation
- Fracture
- AC Separation
- Soft-Tissue Injury

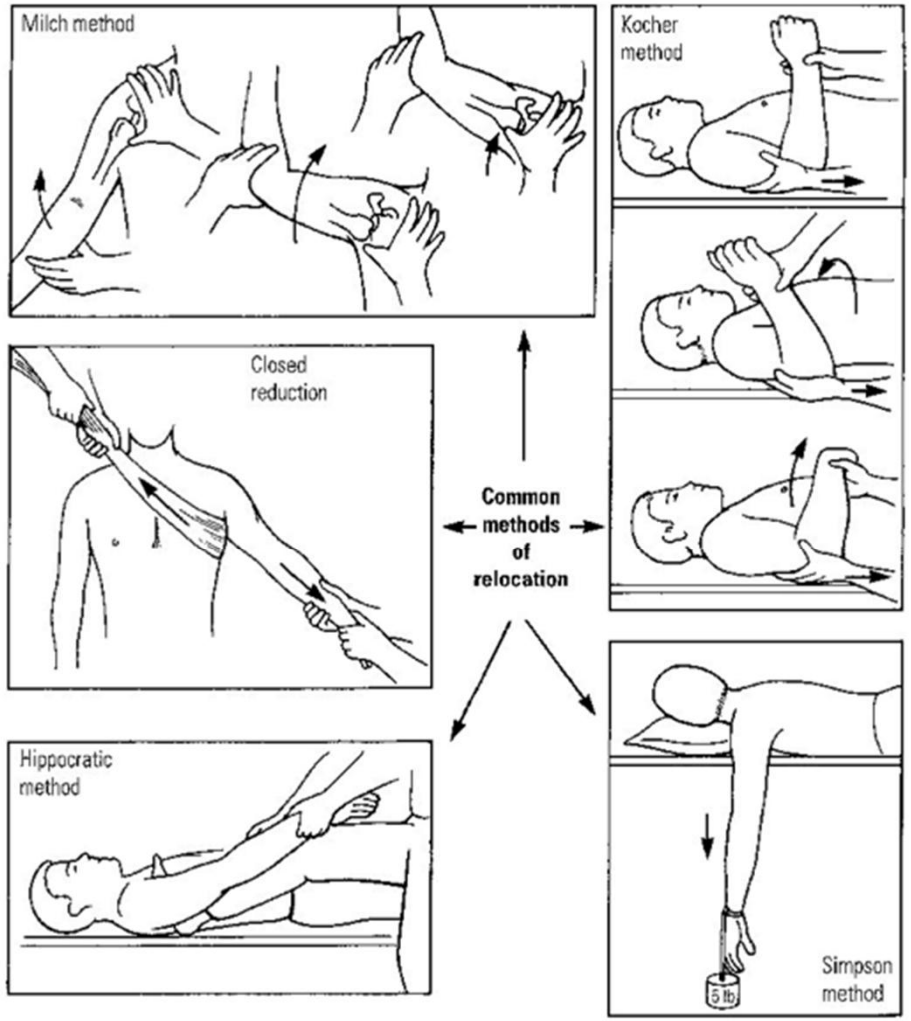

FIG. 17-12 Various methods of reduction of anterior shoulder dislocation.

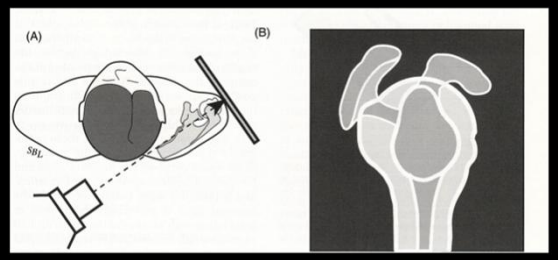

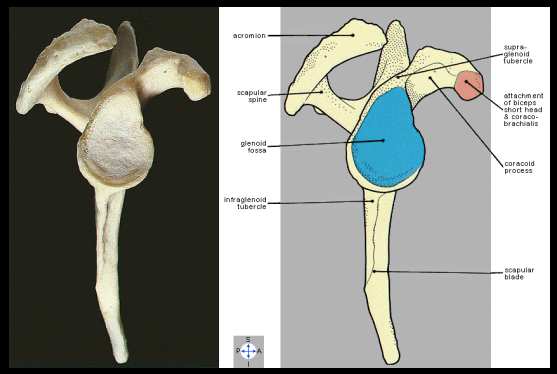

The "Y" View for Dislocations

True AP

Modified Axillary View
(West-Point)

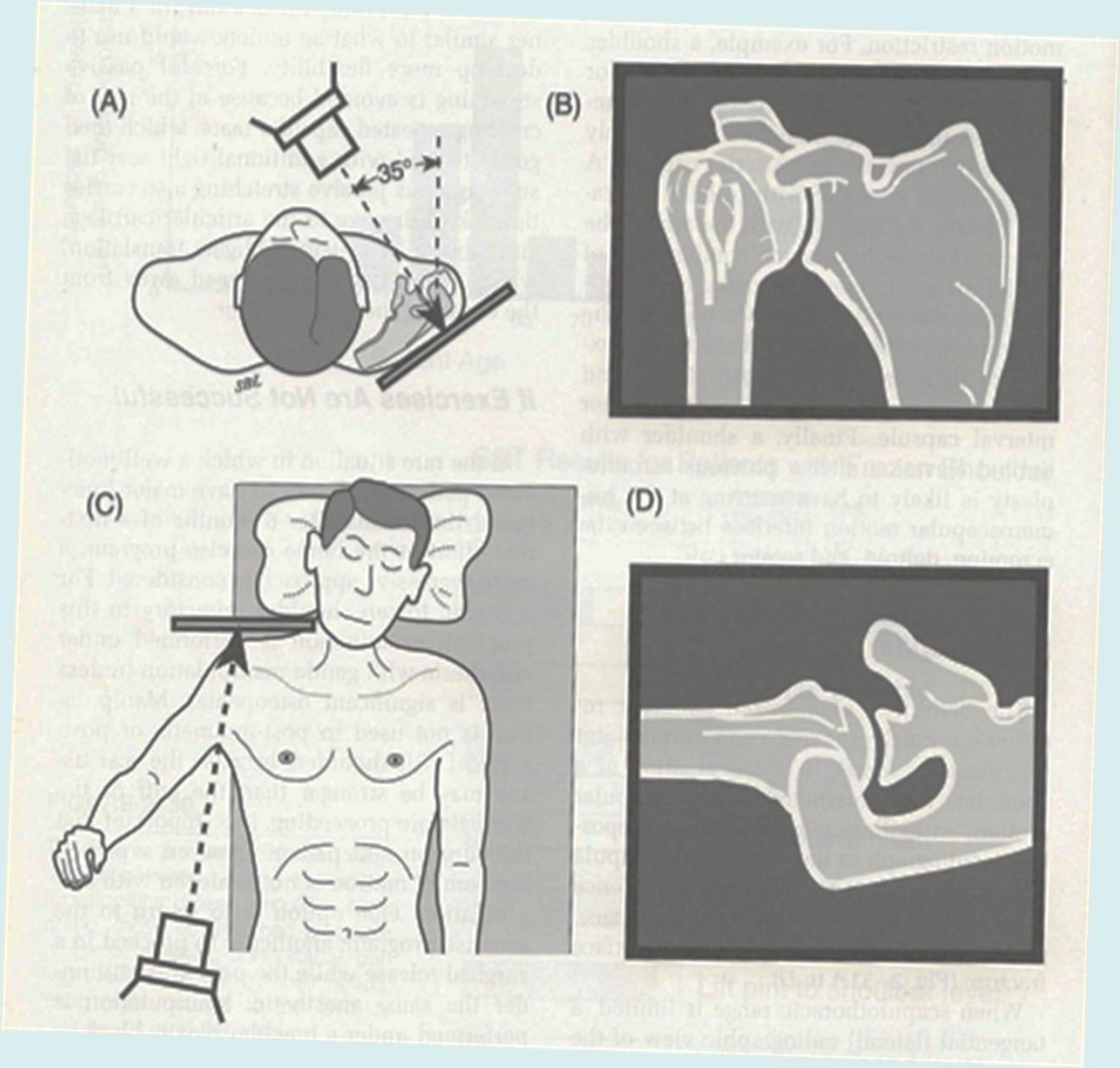

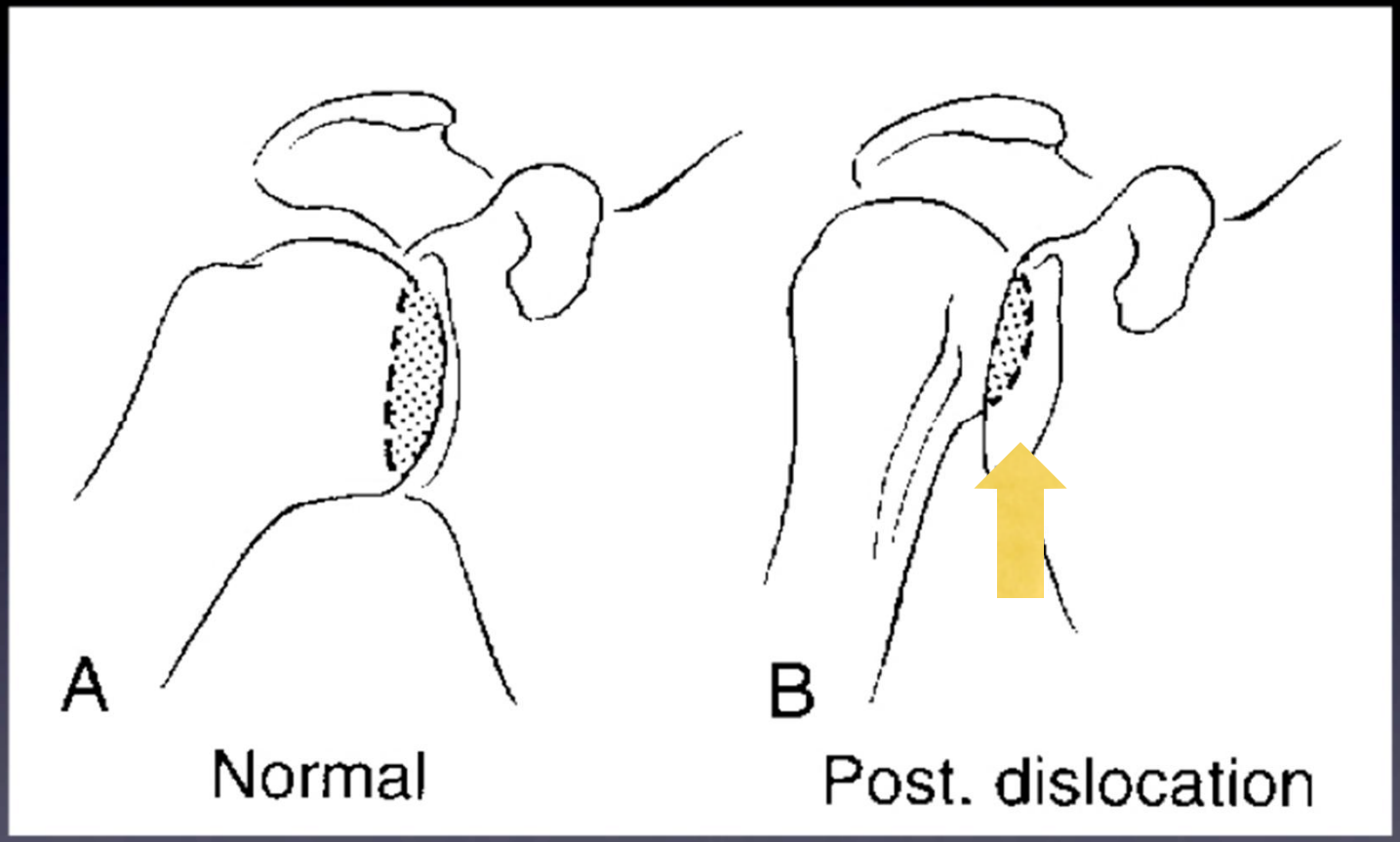

Empty Fossa Sign

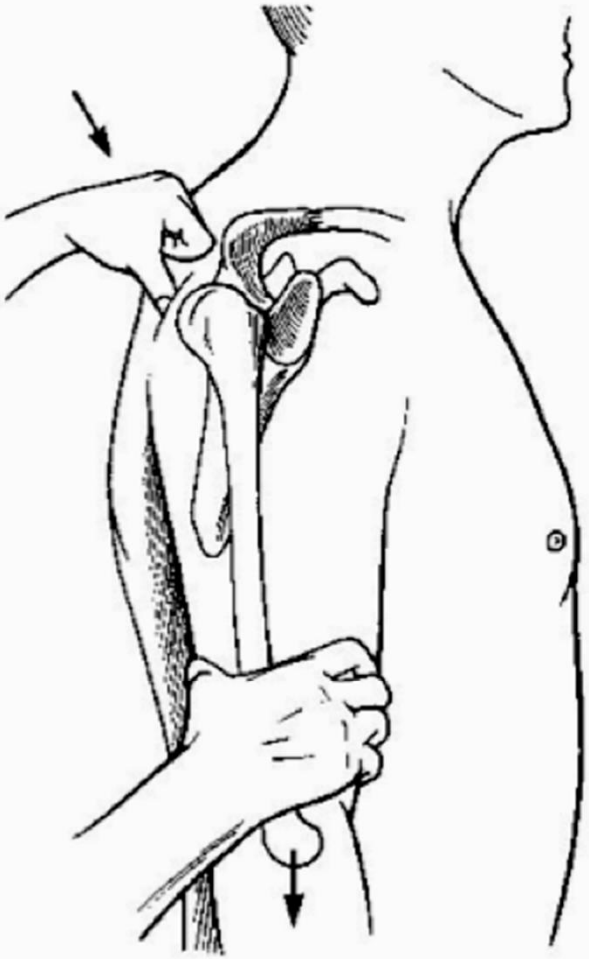

FIG. 17-10 Closed reduction of posterior glenohumeral joint dislocation.

AC Separation

Often fall on out-stretched hand or direct blow. Results in no deformity if 1st degree; deformity for both 2nd and 3rd.

Main determination for surgical stabilization is cosmetic.

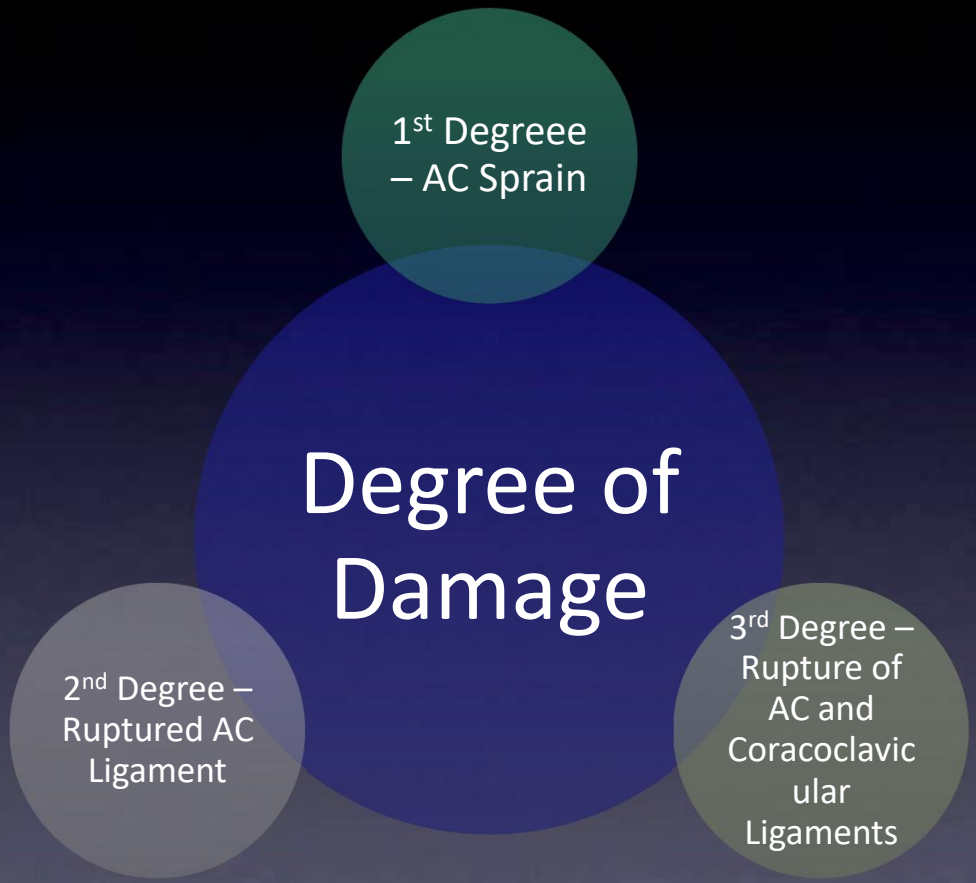

C

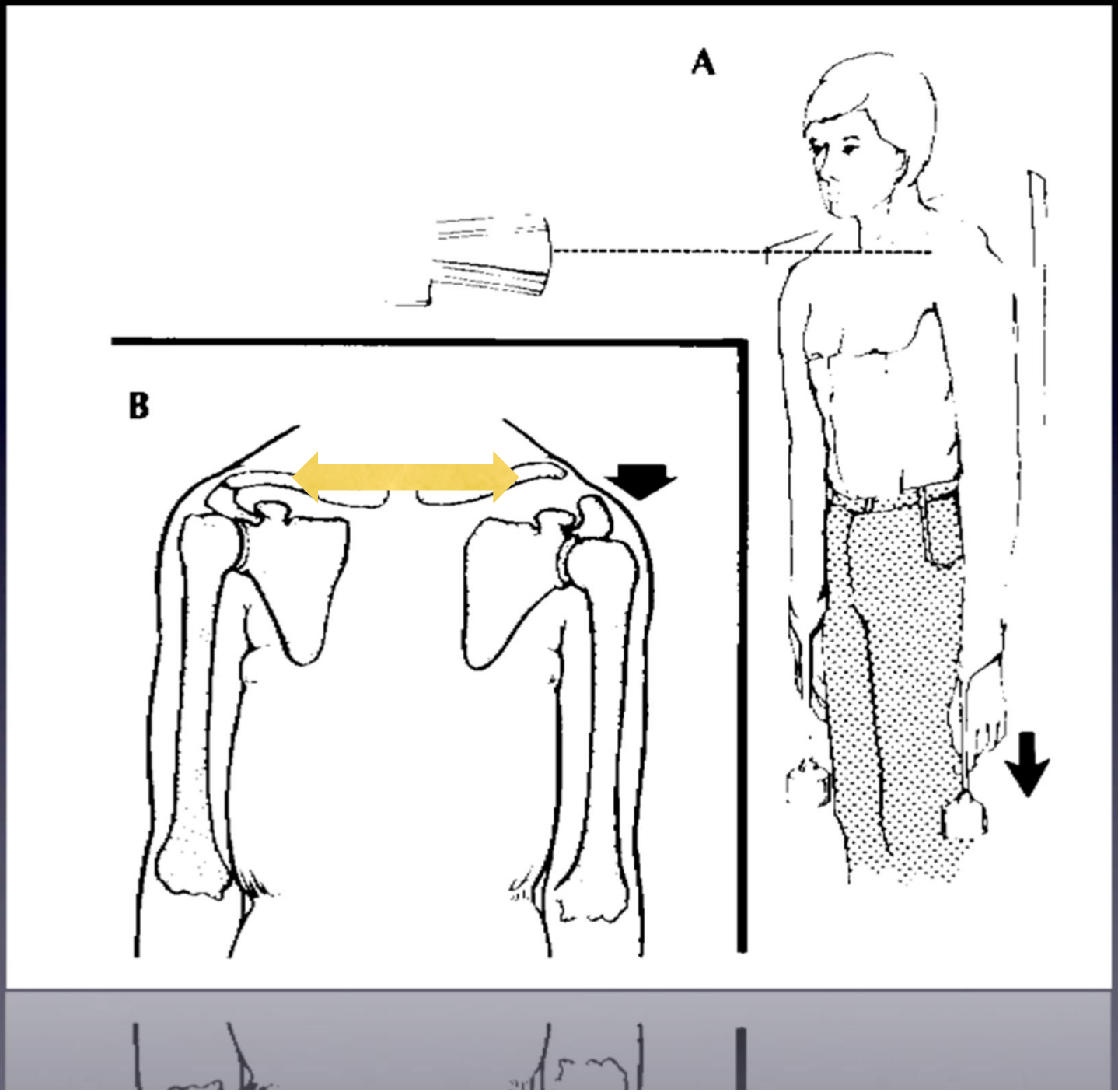
A
B

Kinney-Howard Sling for *relief and immobility*

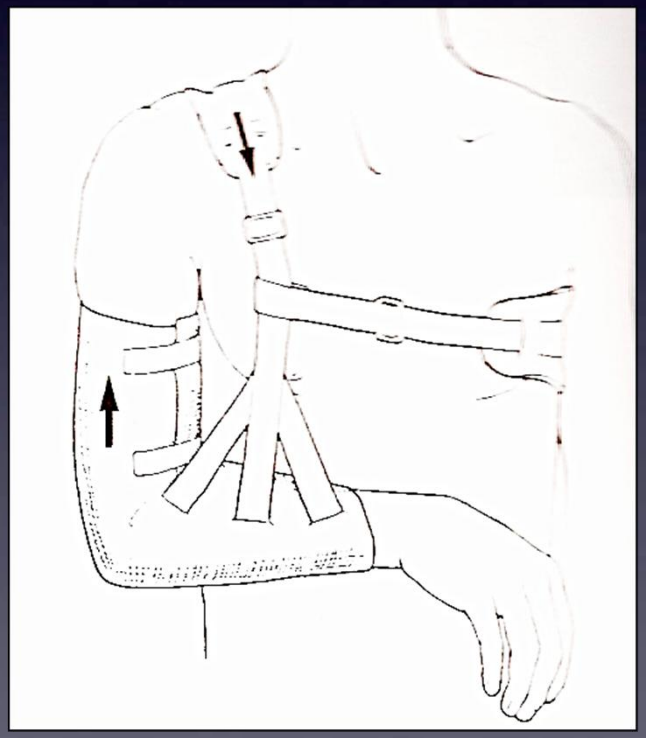

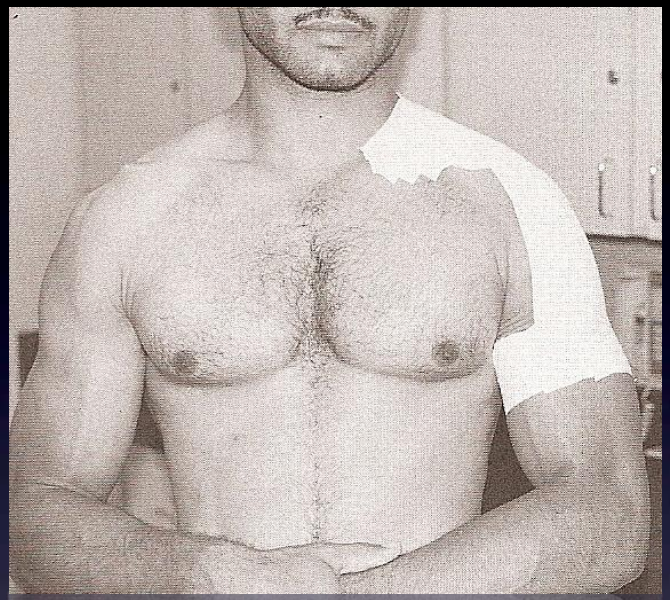

Tape for temporary *relief and* ***mobility***

A 29-year-old power lifter is having pain in his anterior right shoulder.

He bench- presses approximately 300 lbs for 3 sets of 10 as part of his regular routine and is now experiencing pain during the third set, however, not enough to stop him at this time.

He has some difficulty with dips and dead-lifts also

He has had this pain for about 3 weeks. No history of previous trauma

No orthopedic testing is positive

Osteolysis of the Distal Claivicle

- Although it is not uncommon to have osteolysis following AC separation, a non-traumatic type also exists
- Non-traumatic osteolysis of the distal clavicle occurs with heavy weightlifting
- Aggravating/causative maneuvers include the bench-press (wide-grip), clean and jerk, and the dip

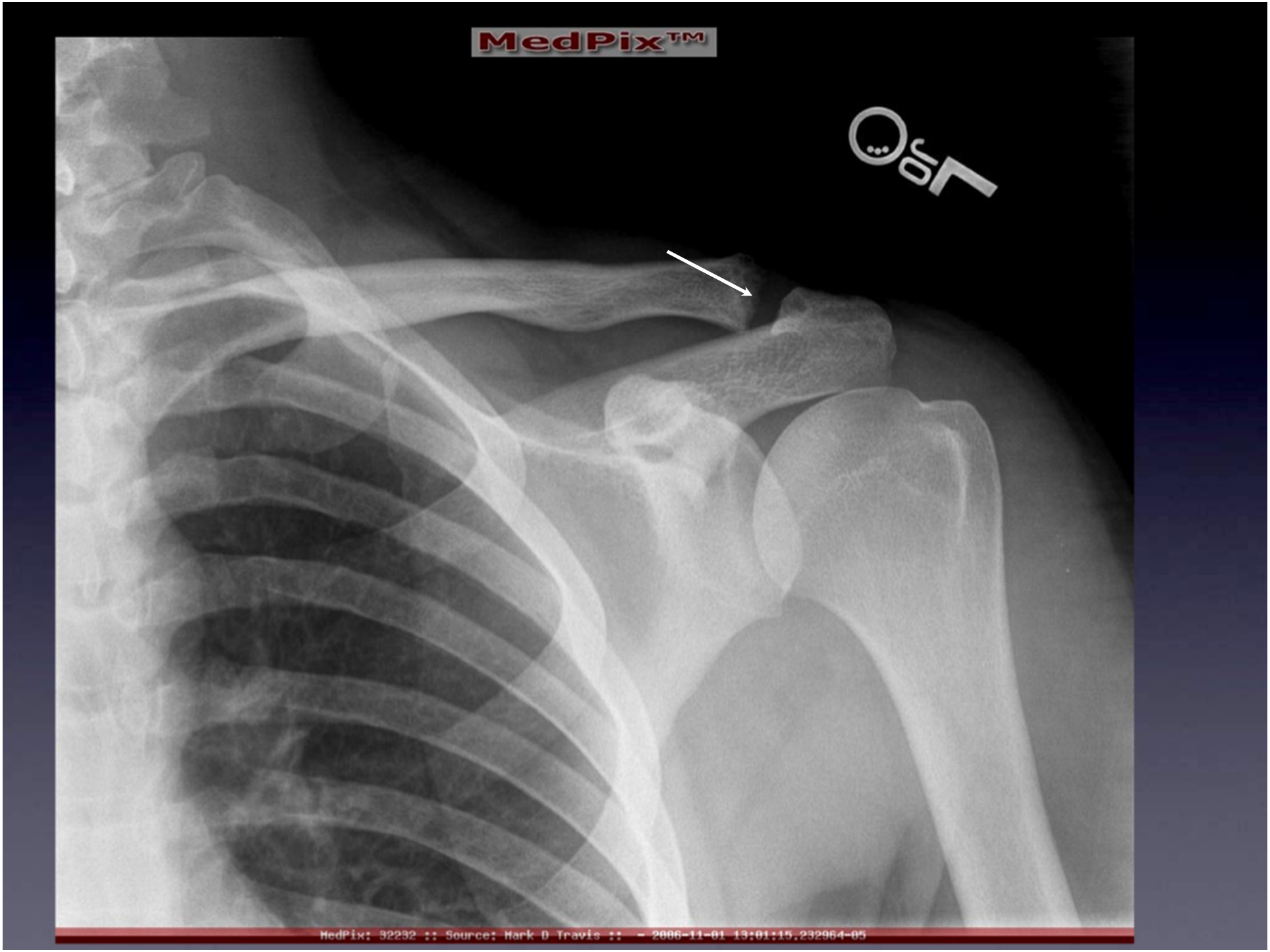
MedPix™
MedPix: 32232 :: Source: Mark D Travis :: - 2006-11-01 13:01:15.232964-05

- Avoidance is the first step to treatment followed by modification including:
  - substitute bench-press with incline/decline presses or crossover pulley
  - If bench press is used modify to close-grip and less weight
- If not improved in 6 months surgical option is acromioplasty

A 24-year old female patient presents with left shoulder pain.

The pain is felt anteriorly and seemed to begin while training.

She is a high level free-style swimmer who also does some weight training.

She is unable to swim due to pain and cannot perform any weightlifting movements above shoulder level.

She has had no history of dislocation or fracture.

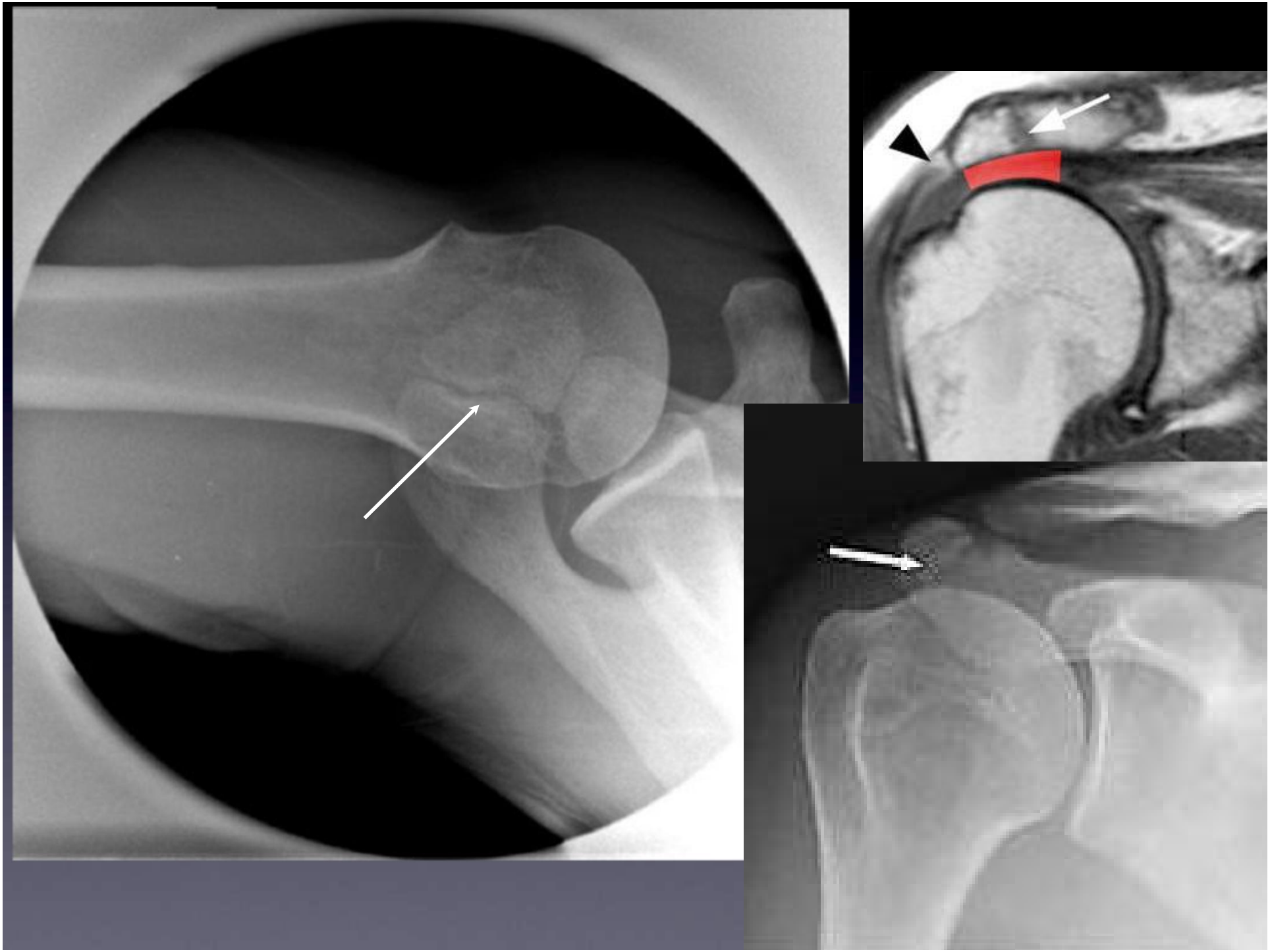

What Does the Literature Say About the Examination for the Shoulder?

Stability

Static vs dynamic and the <u>overlap</u> between the two

Glenohumeral and/or Scapular

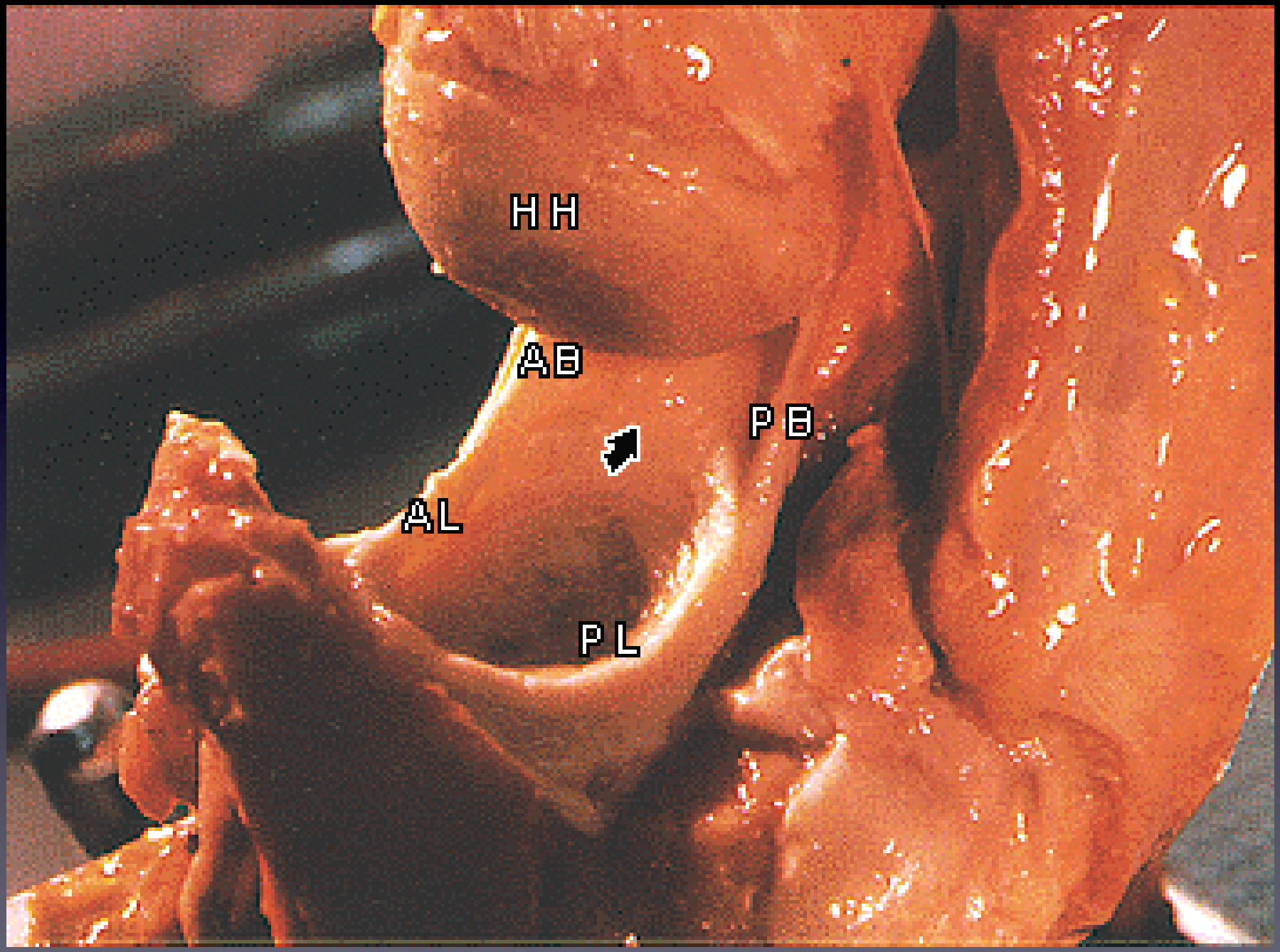
HH
AB
PB
AL
PL

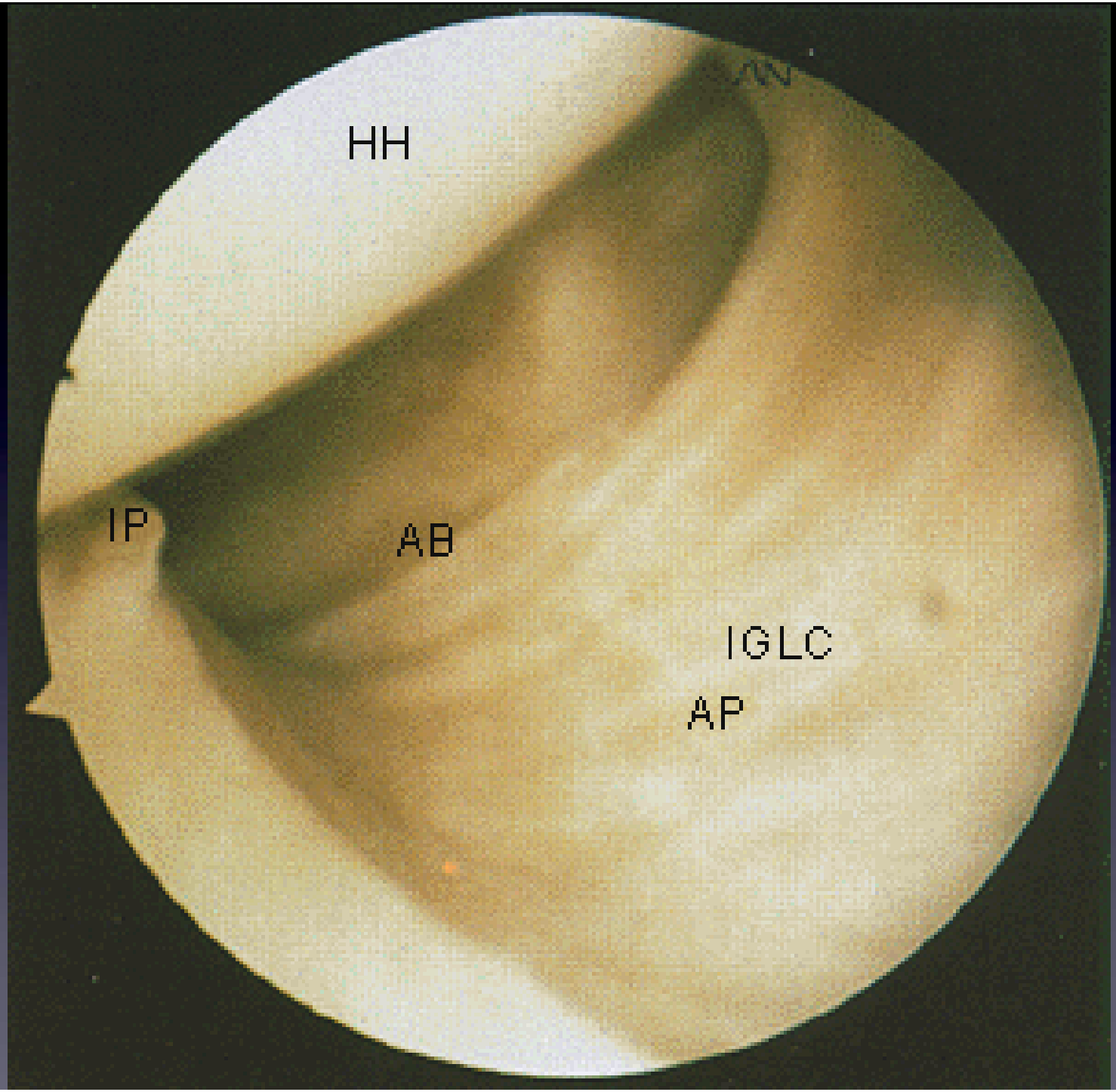
HH
IP
AB
IGLC
AP

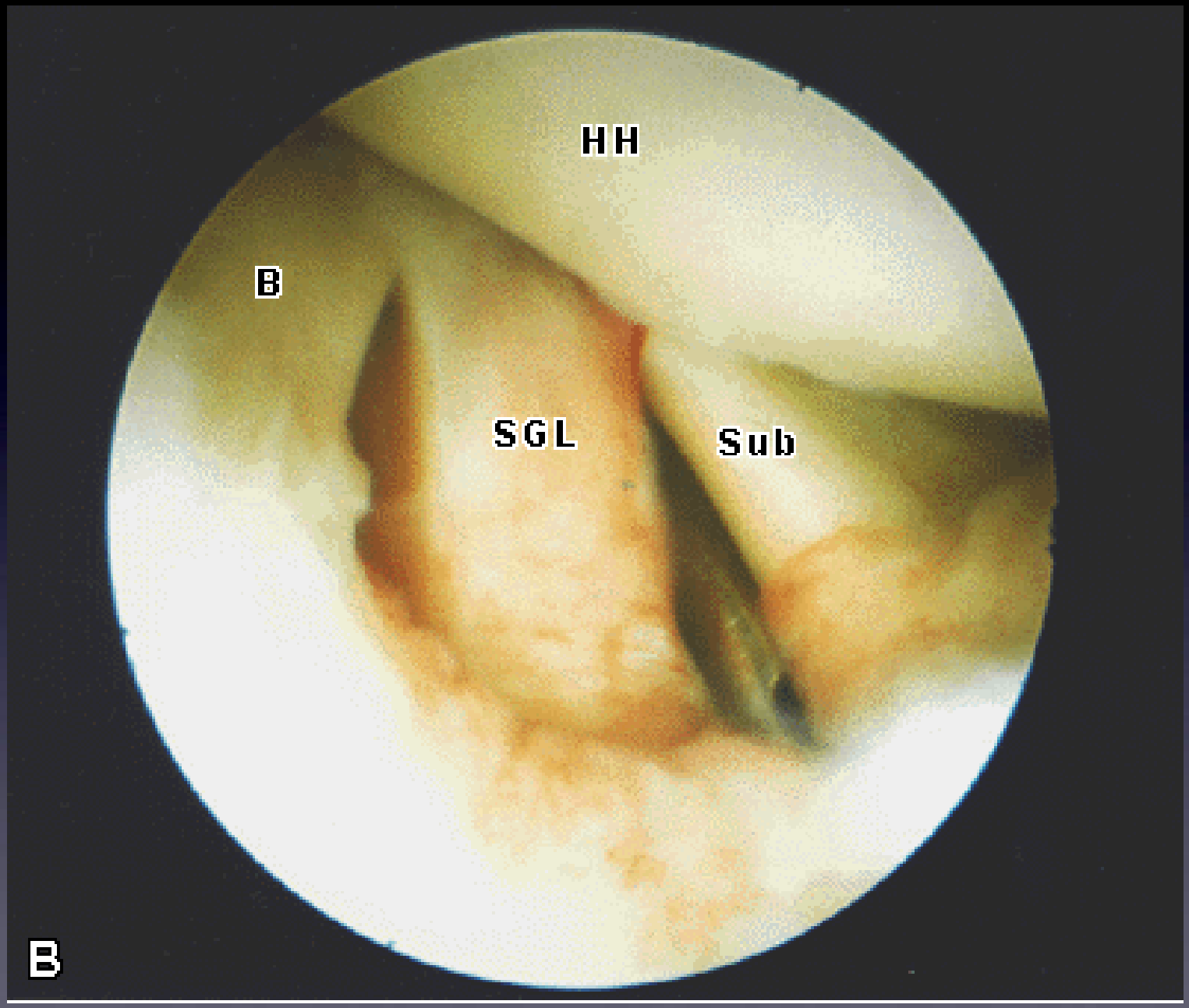
HH
B
SGL
Sub
B

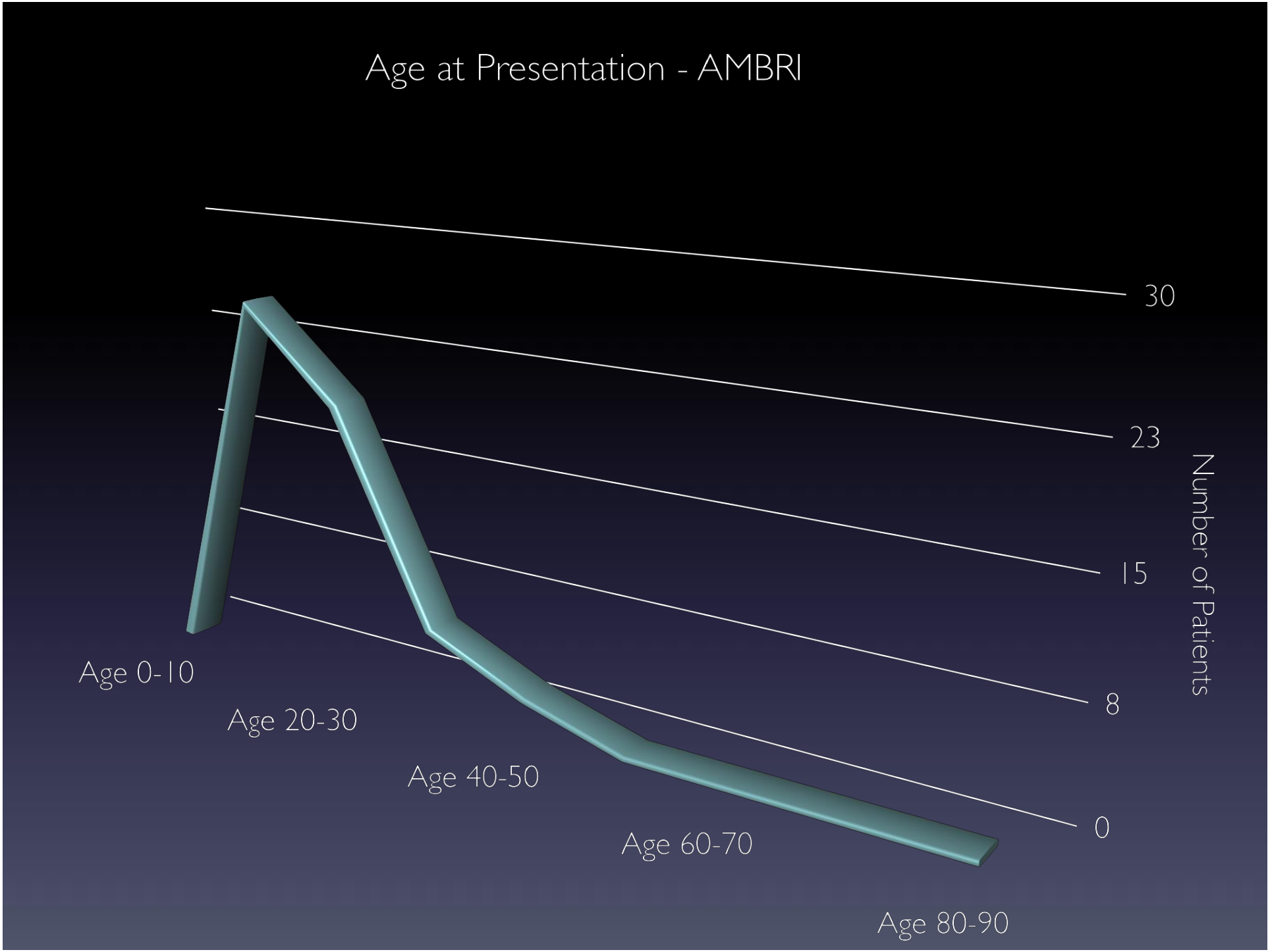
Age at Presentation - AMBRI
30
23
15
8
0
Number of Patients
Age 0-10
Age 20-30
Age 40-50
Age 60-70
Age 80-90

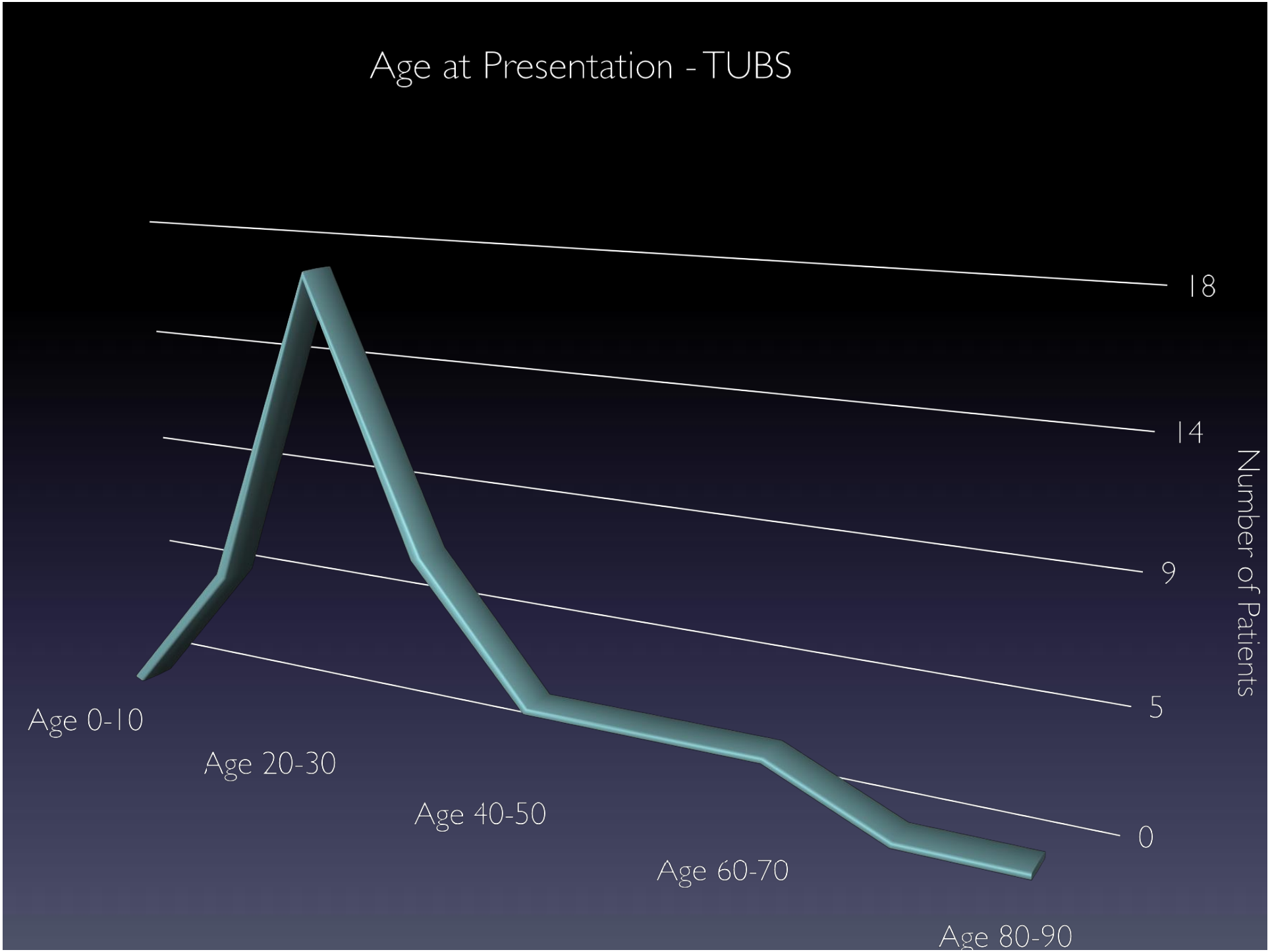
Age at Presentation - TUBS
18
14
9
5
0
Number of Patients
Age 0-10
Age 20-30
Age 40-50
Age 60-70
Age 80-90

The **Apprehension** test is most valuable for identifying **instability** when "apprehension" is the positive finding

The **combination** of the **anterior apprehension test and Jobe relocation tests** may be of value in

identifying but not ruling-out labrum tears

For ruling-in and ruling-out ***labrum tears*** the combination of:

the crank, apprehension, relocation, load-and-shift, and inferior sulcus sign

may be of value

The Load and Shift Tests

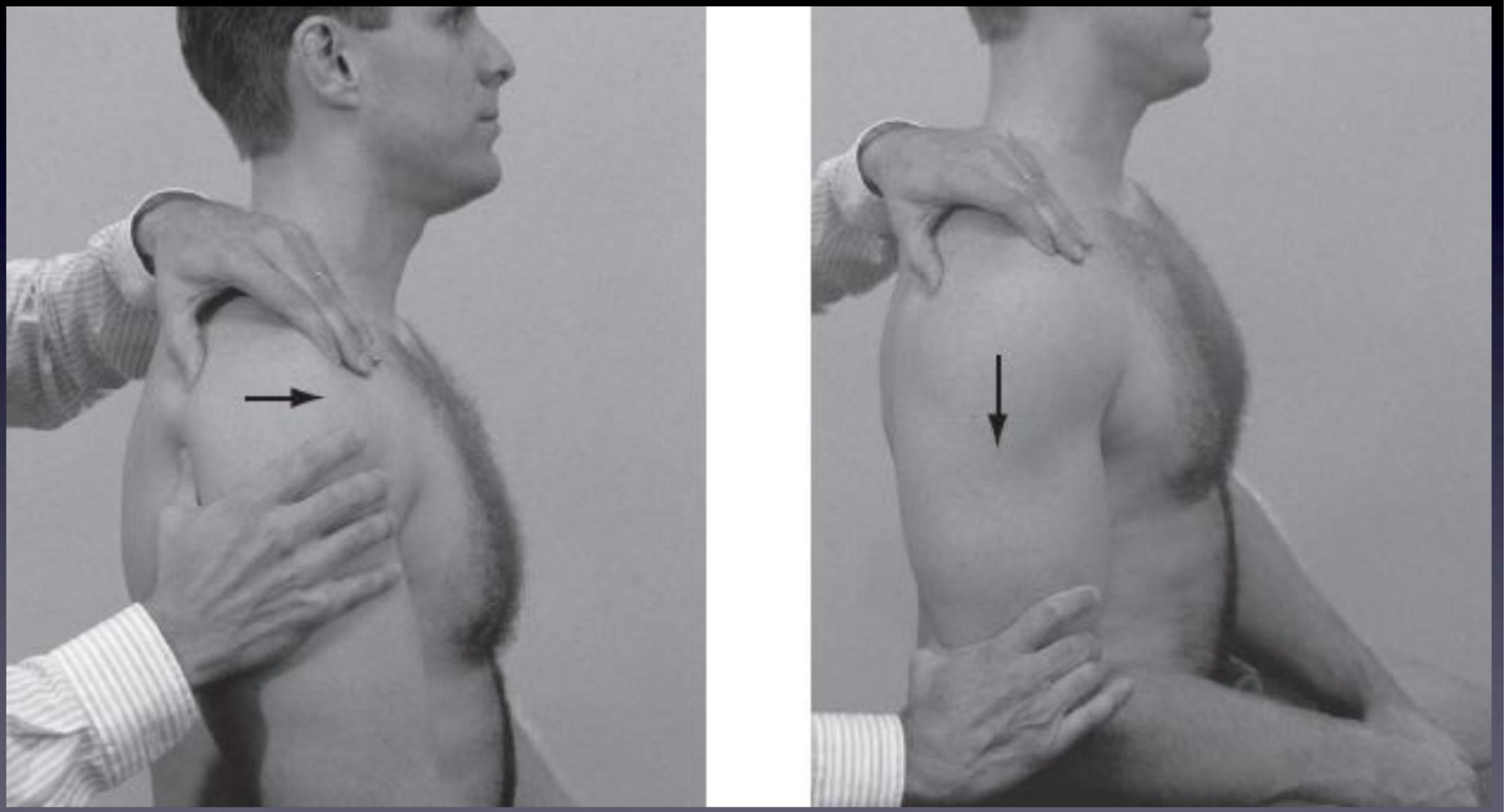

The Apprehension and Relocation Tests

Relocation Test

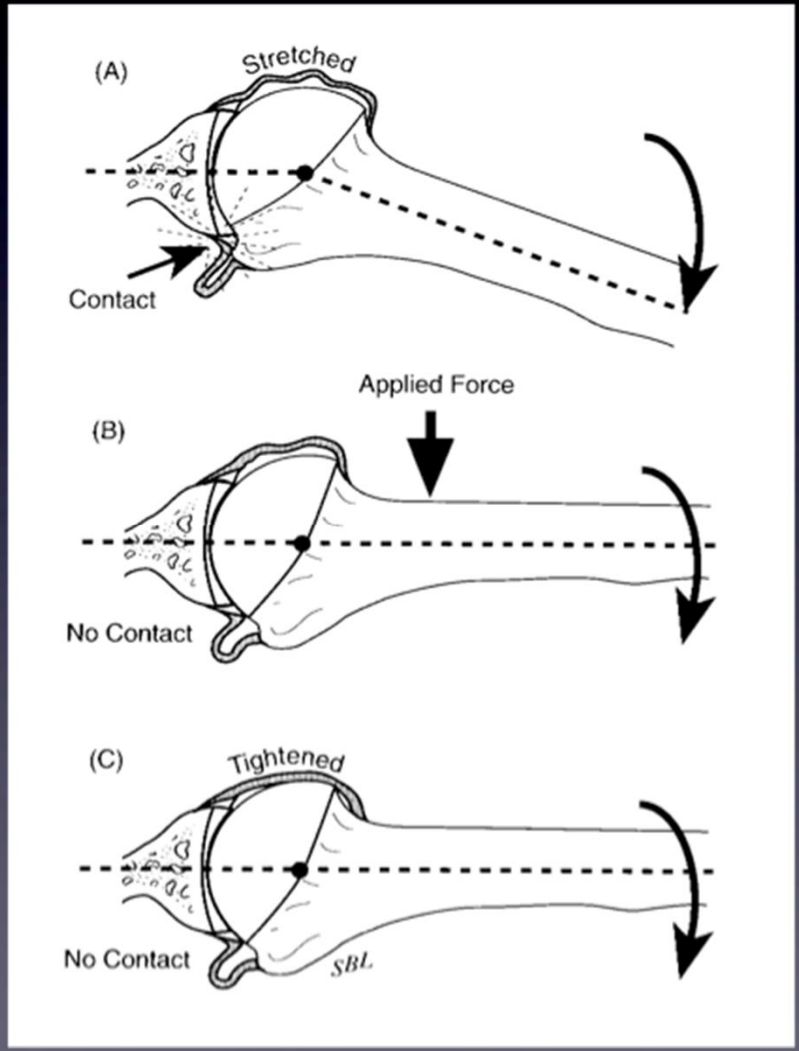

The Crank Test

Which type of tear?

Most anterior dislocations result in a

posterior-inferior labrum tear

Over-contraction of the biceps leads to a SLAP lesion: *Superior Laburm, Anterior to Posterior*

Shoulder

Arm

Elbow

Forearm

Wrist

Hand

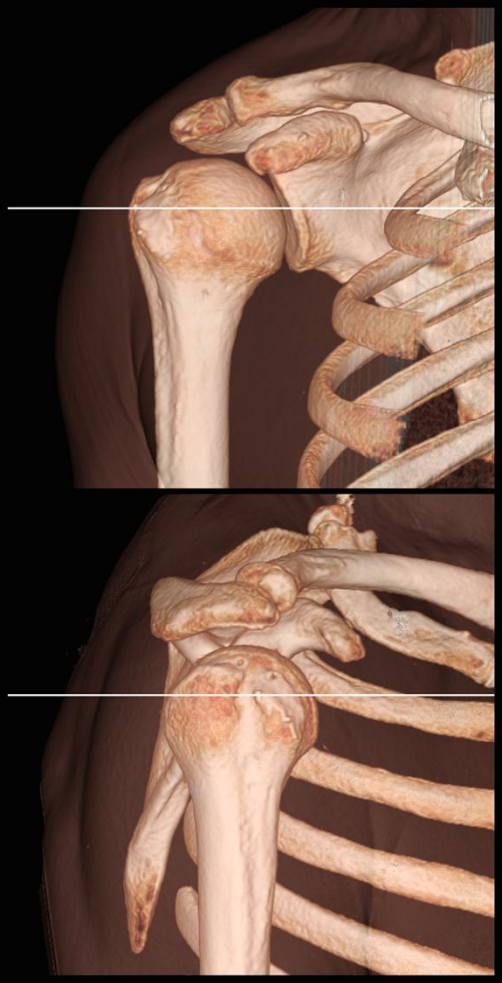

Posteroinferior glenoid labrum

Posterior Inferior Tears

Kim Test

Passively elevating the shoulder to 90 degrees, the examiner applies an axial load while simultaneously lifting the distal humerus to impose a posterior-inferior load to the shoulder.

Posterior Inferior Tears

Jerk Test

Involves passive elevation of the shoulder to 90 degrees, however, in this test, the scapula is stabilized. The examiner then imparts an axial compression while simultaneously horizontally adducting the shoulder across the chest.

SLAP Lesions

Vulnerable to sudden over-contraction is the long-head of the biceps at its origin, the superior glenoid rim and the attached labrum

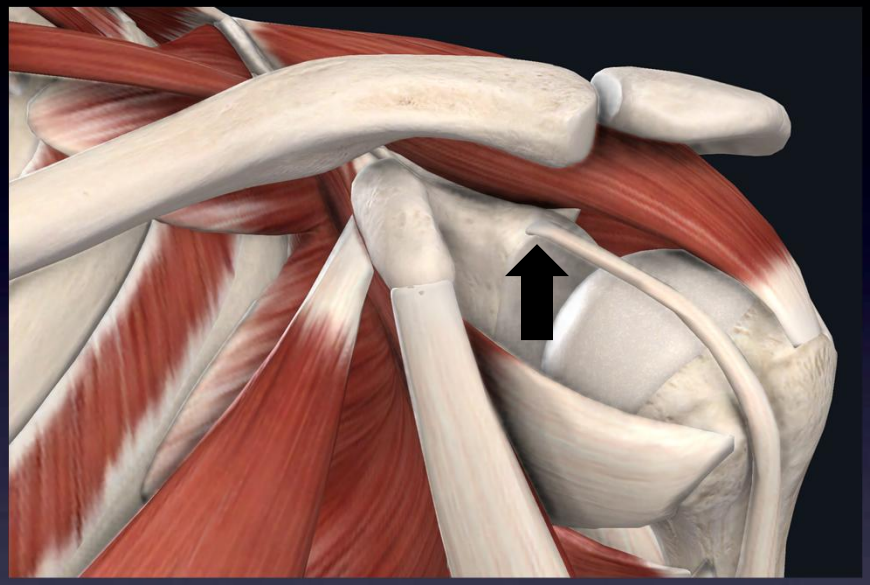

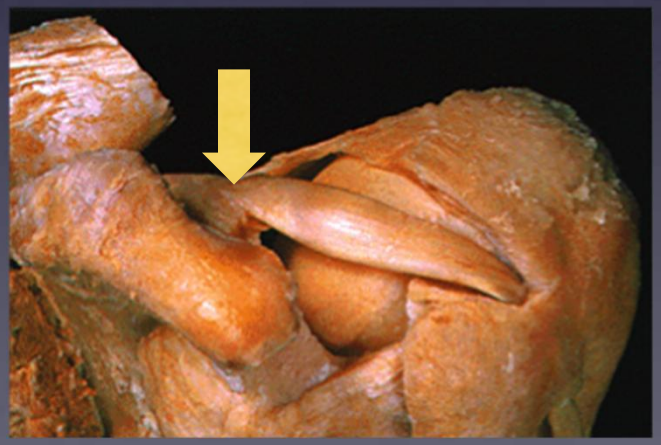

Shoulder

Arm

Elbow

Forearm

Wrist

Hand

Superior glenoid labrum

Axial | Coronal | Sagittal | Bones | Joints | Muscles | Vessels | Nerves

Shoulder

Arm

Elbow

Forearm

Wrist

Hand

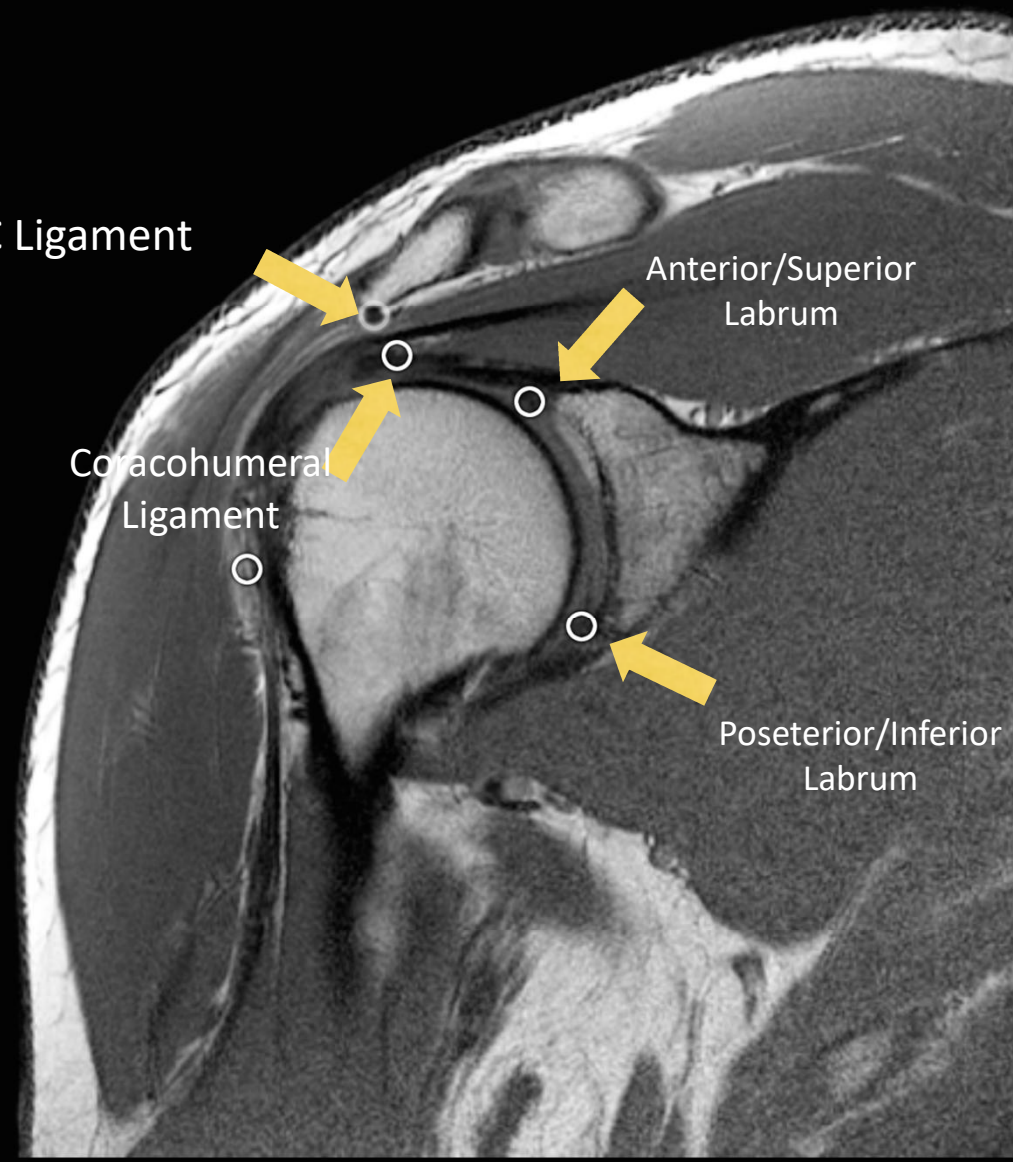

Acromioclavicular I.

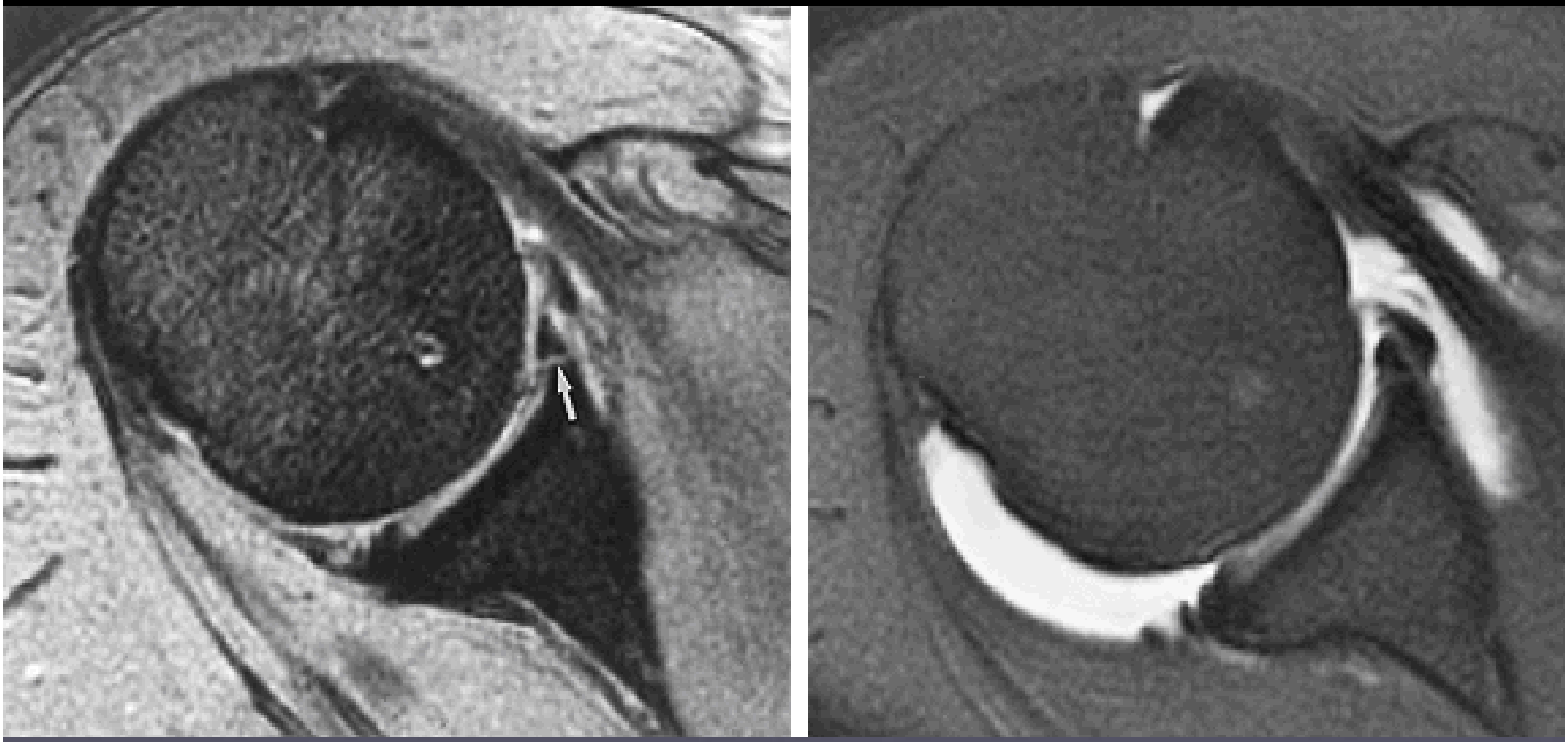

For ruling-in or ruling-out *SLAP lesions,* **combining**:

two highly s**ensitive tests**

(compression rotation (Crank), anterior apprehension, and O'Brien tests)

with

one **specific test**

(Yergason, biceps I & II and Speeds tests) may be helpful whereas

individually, the tests are of little value

Yergason's Test

Forearm flexion and supiinatiion are resisted at 90 degrees elbow flexion

SLAP Lesions

The Active Compression: "O'Brien Test"

Similar to the Empty Can test but performed at 10 degrees horizontal adduction

Position 1 is painful; position to relieves or alleviates pain

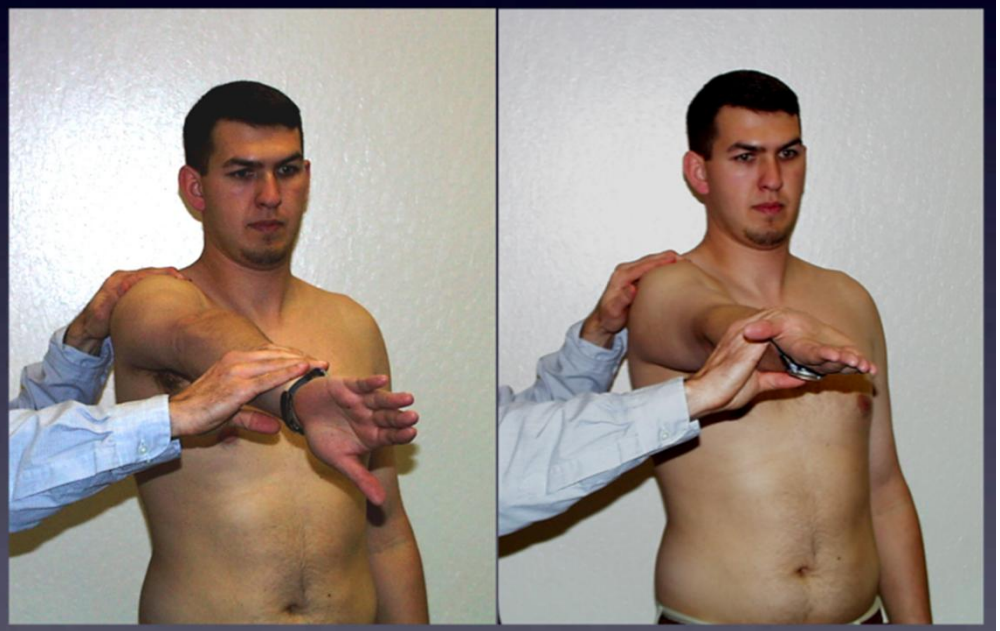

SLAP Lesions

Biceps Load II Test

The test is performed by passively elevating the supine patients arm to 120º abduction and maximal, external rotation. The elbow is bent to 90º of flexion and the forearm is supinated. The examiner then asks the patient to flex the elbow while the examiner resists this attempt.

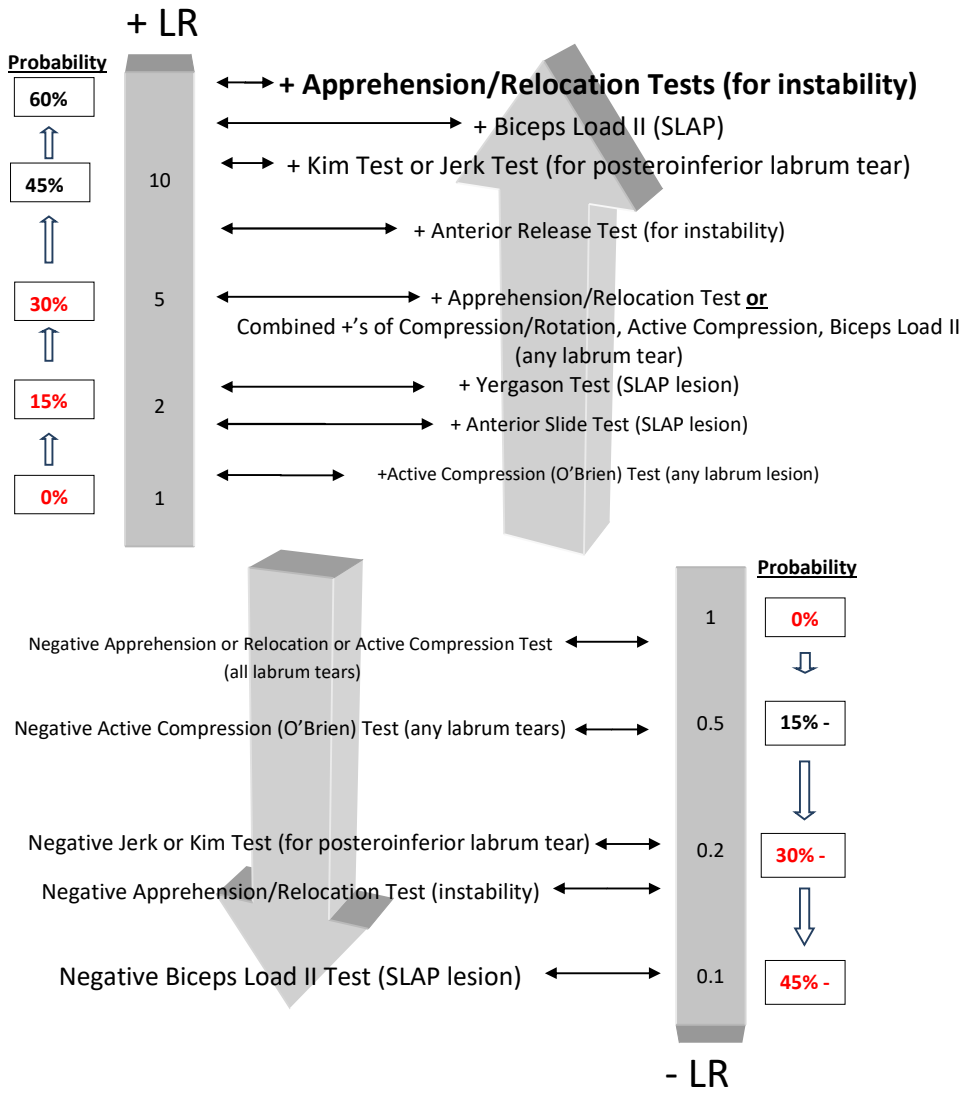

Exhibit 7-1: Likelihood Patient Has Instability and/or a Labrum Tear

Subacromial
"Outlet"

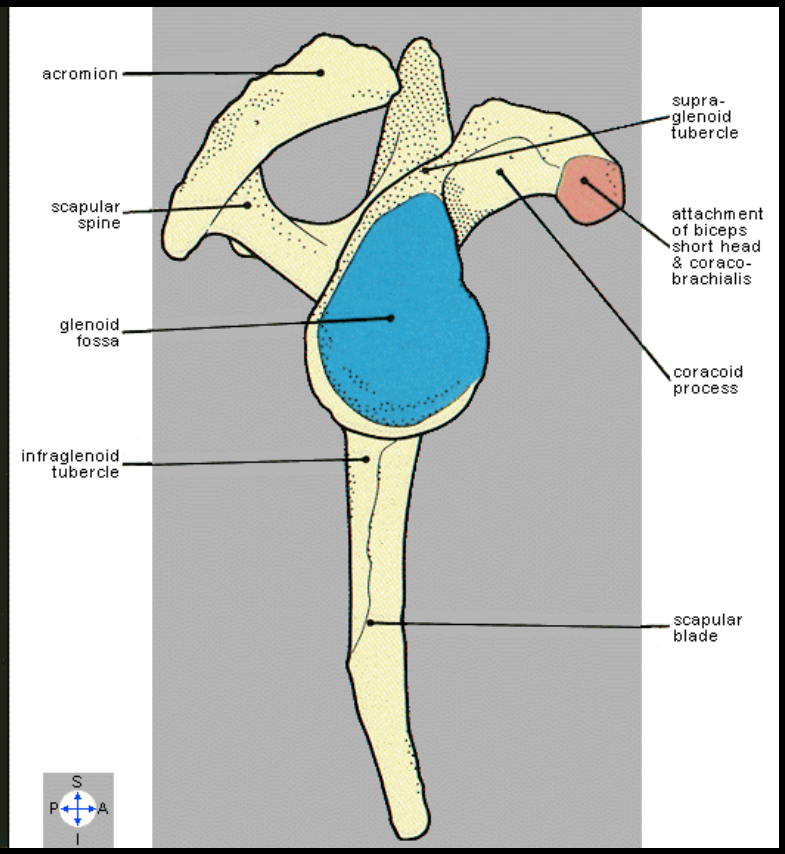

Subacromial Impingement

Subacromial Impingement

Compression of soft tissue structures in the subacromial outlet formed by supraclavicular fossa on the bottom and the acromioclavicular joint and specifically the coracoacromial ligament on the top

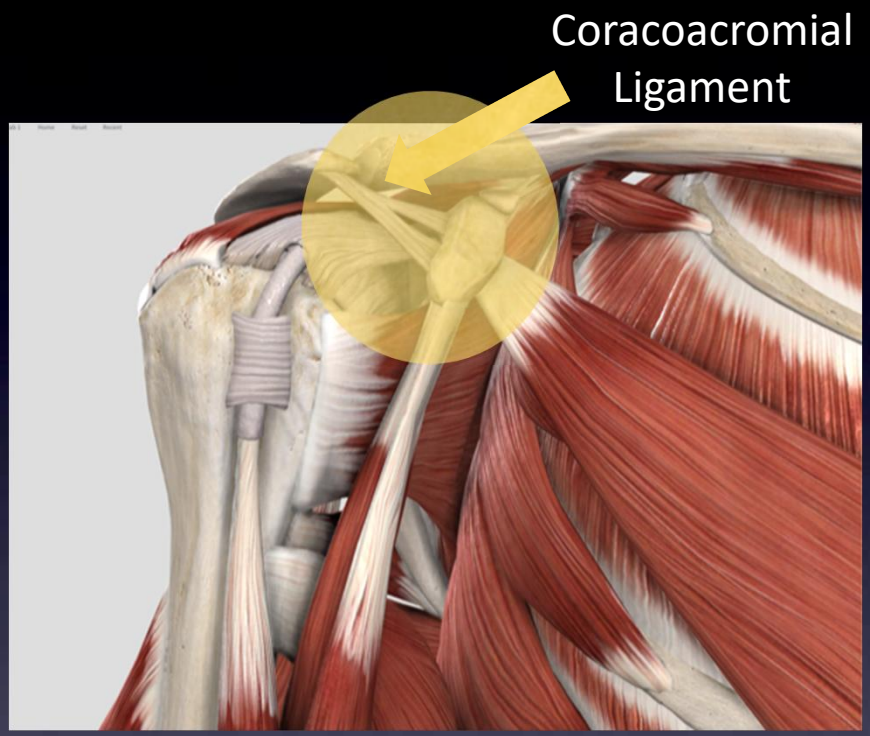

Structures affected include:

- Long head of biceps tendon
- Supraspinatus tendon
- Subacromial bursa

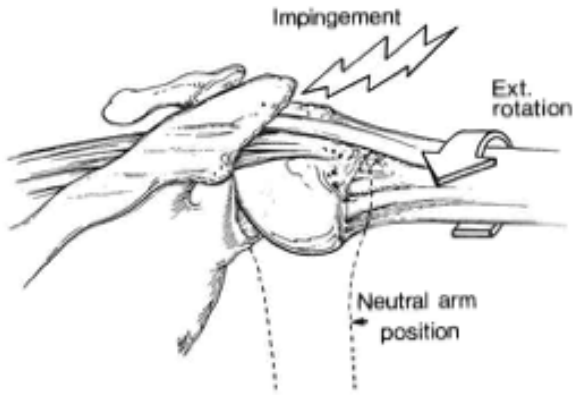

Fig. 14-7. Group 1: impingement. (From Jobe and Bradley,[102] with permission.)

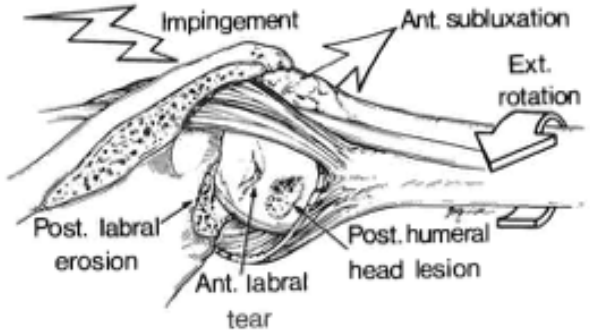

Fig. 14-8. Group 2: anterior instability due to chronic microtrauma. (From Jobe and Bradley,[102] with permission.)

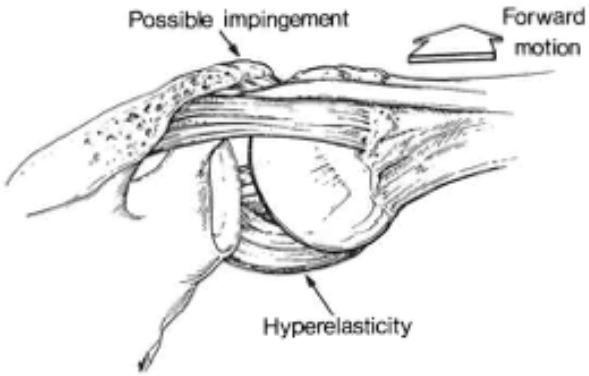

Fig. 14-9. Group 3: instability due to hyperelasticity. (From Jobe and Bradley,[102] with permission.)

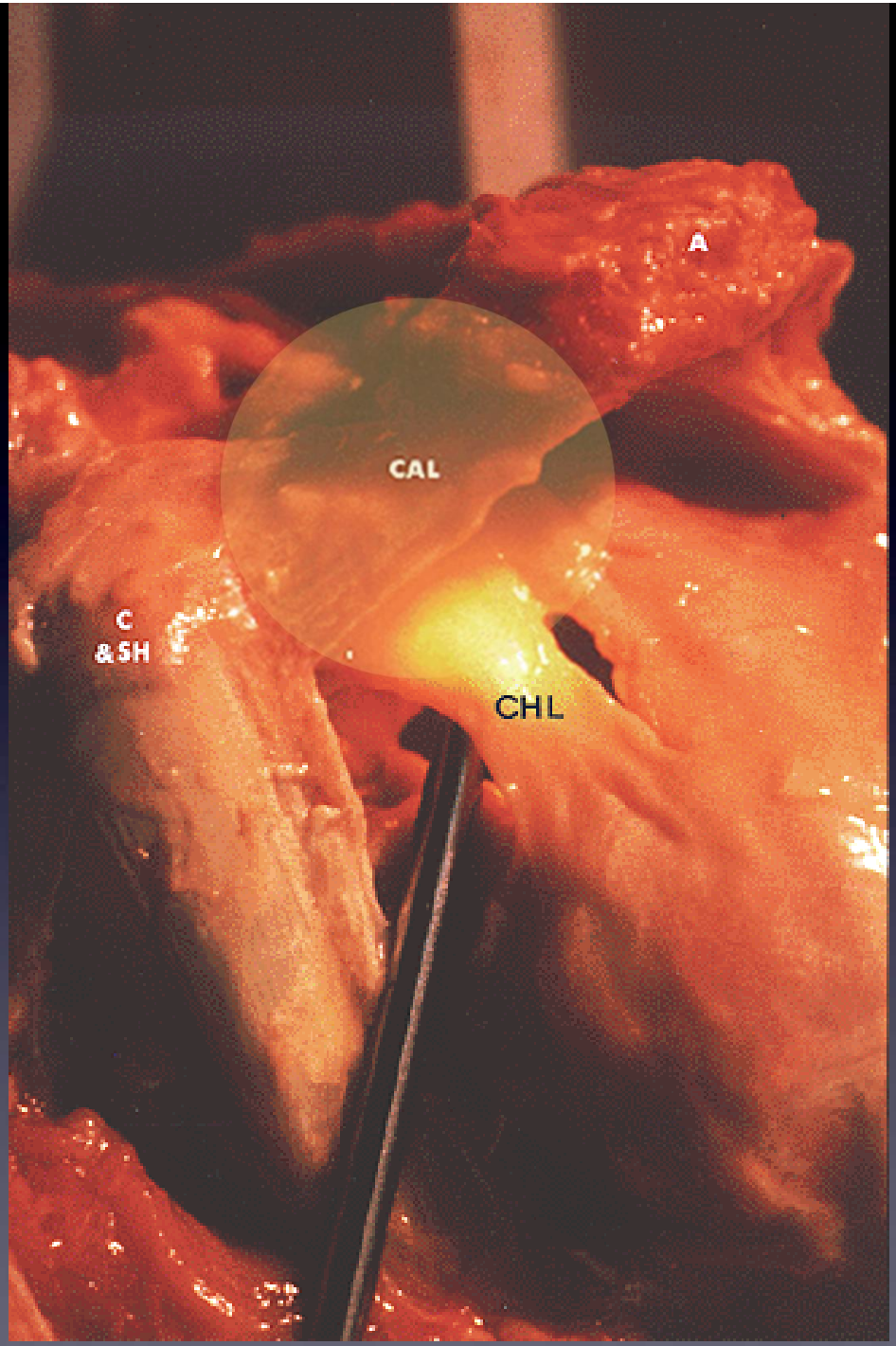

Compression occurs mainly from the coracoacromial ligament (CAL) with the arm elevated

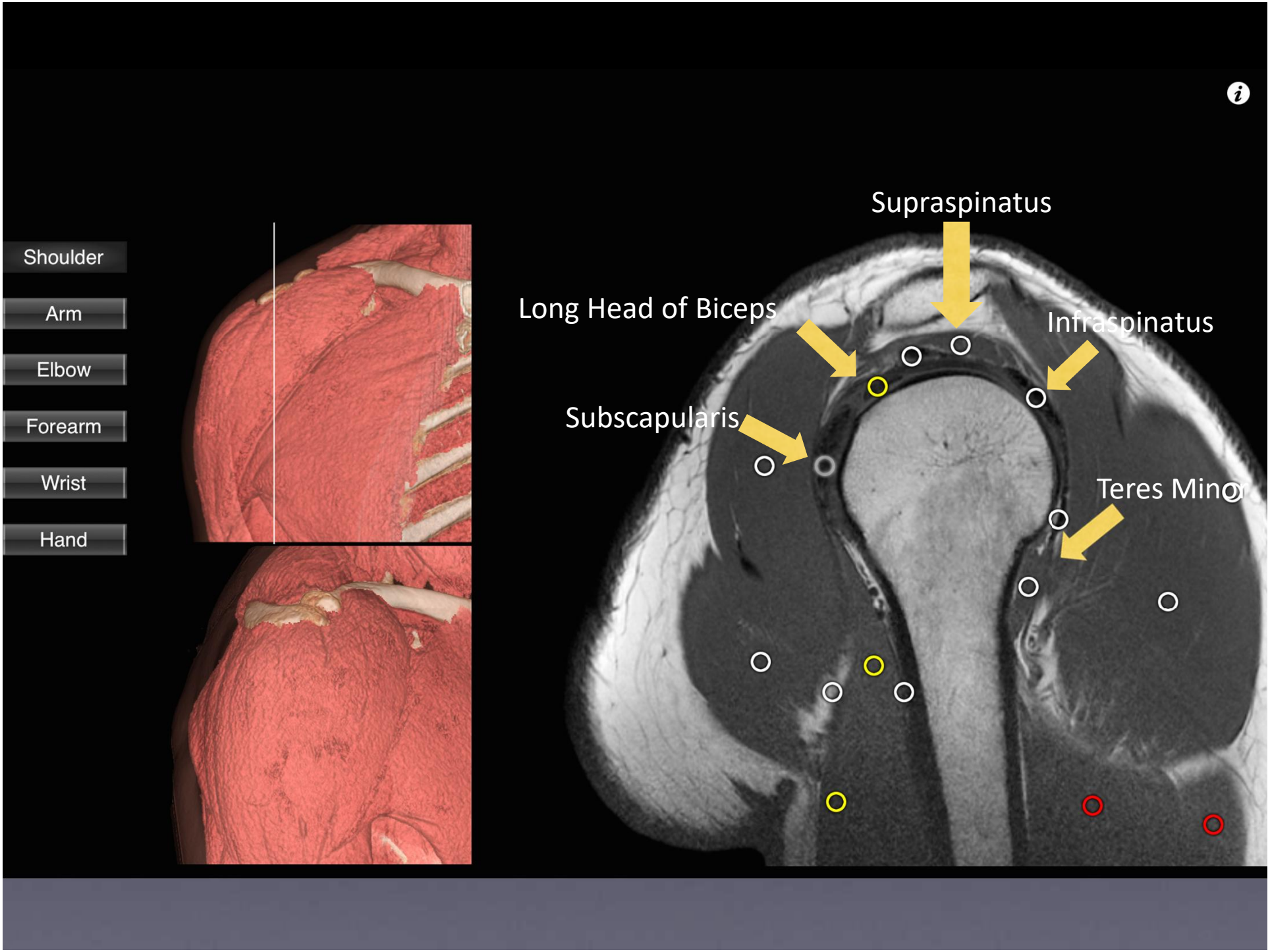
Shoulder
Arm
Elbow
Forearm
Wrist
Hand
Supraspinatus
Long Head of Biceps
Infraspinatus
Subscapularis
Teres Minor

Shoulder

Arm

Elbow

Forearm

Wrist

Hand

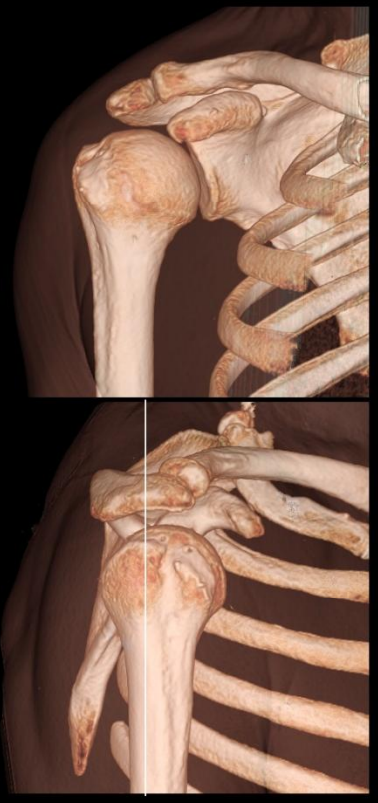

Subacromiodeltoid bursa

Axial | Coronal | Sagittal | Bones | Joints | Muscles | Vessels | Nerves

For **subacromial impingement:**

The Hawkins-Kennedy and Neer tests *together* may be helpful in ruling-in or ruling-out impingement

The *painful arc* may add useful support for a diagnosis of impingement

Impingement Syndrome

- Park study, 913 patients underwent physical examination and diagnostic arthroscopy (Quality Rating = 69).
- The physical examination included eight clinical tests: Hawkins-Kennedy, Neer's, empty-can, Speeds, cross-body adduction, infraspinatus strength test, drop-arm sign, and painful arc.
- Results indicated that:

The combination of the Hawkins-Kennedy, painful arc, and infraspinatus muscle tests yielded the best post-test probability (95%) for any degree of impingement

Impingement Tests

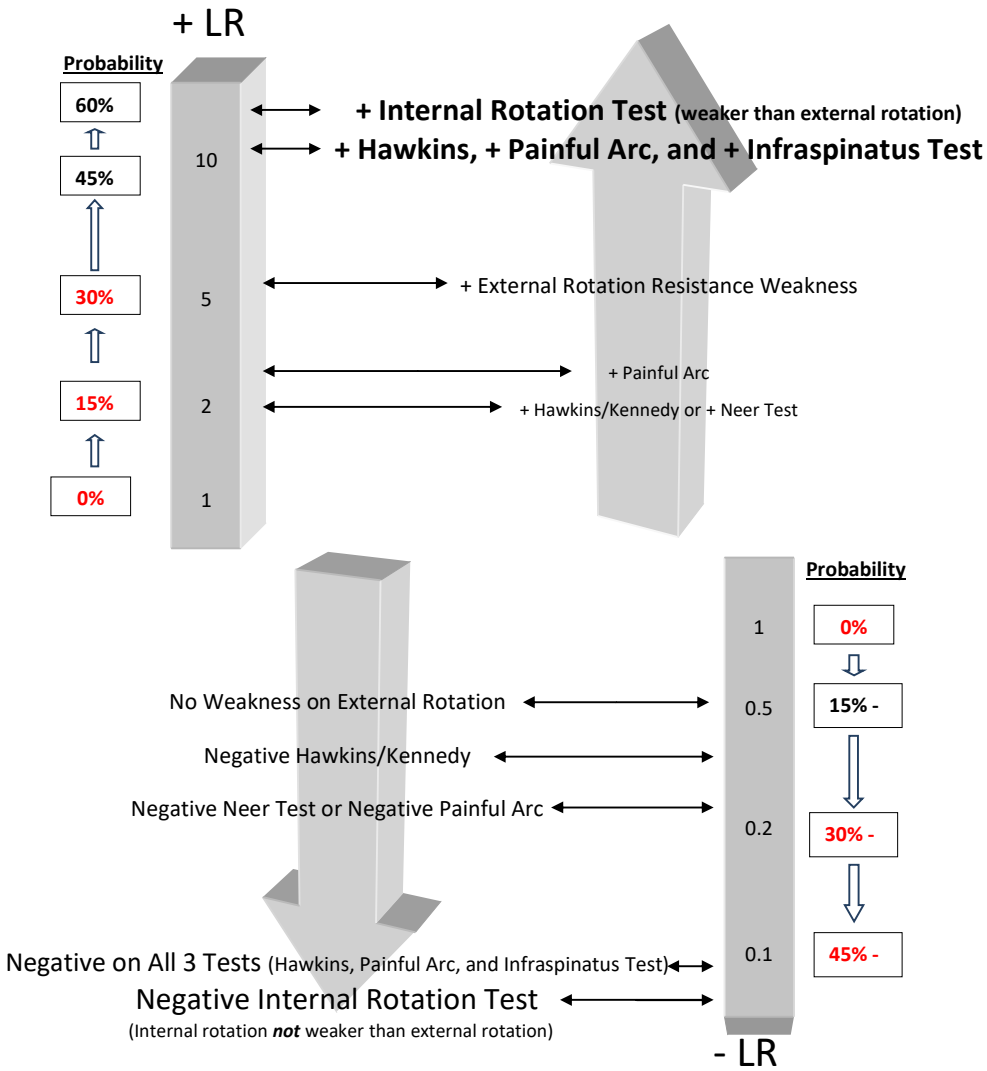

Exhibit 7-2: Likelihood Patient Has Subacromial Impingement

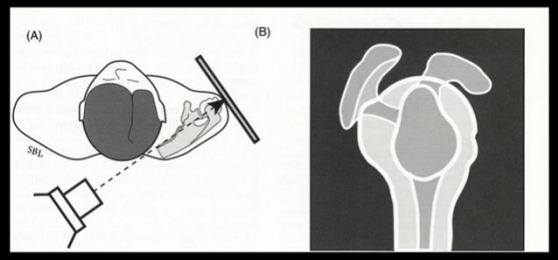

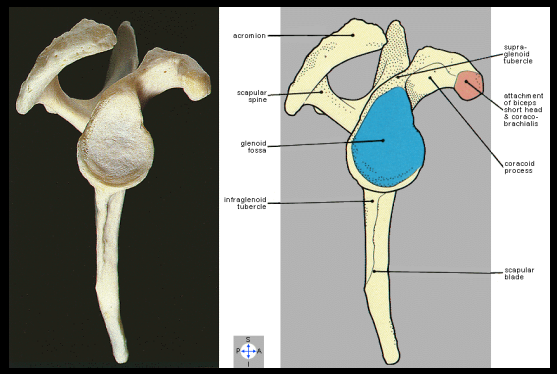

The Outlet View for Bony Impingement

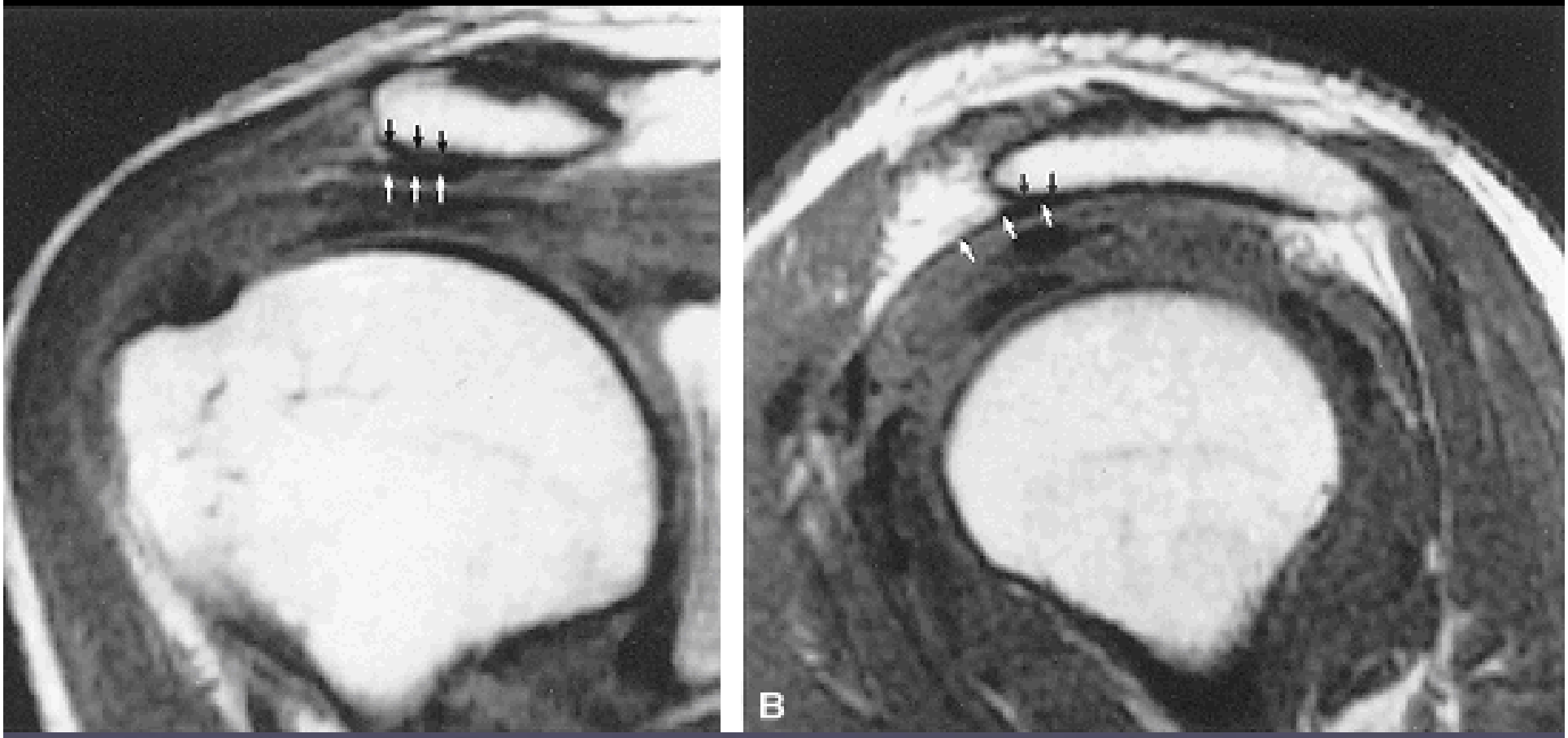
B

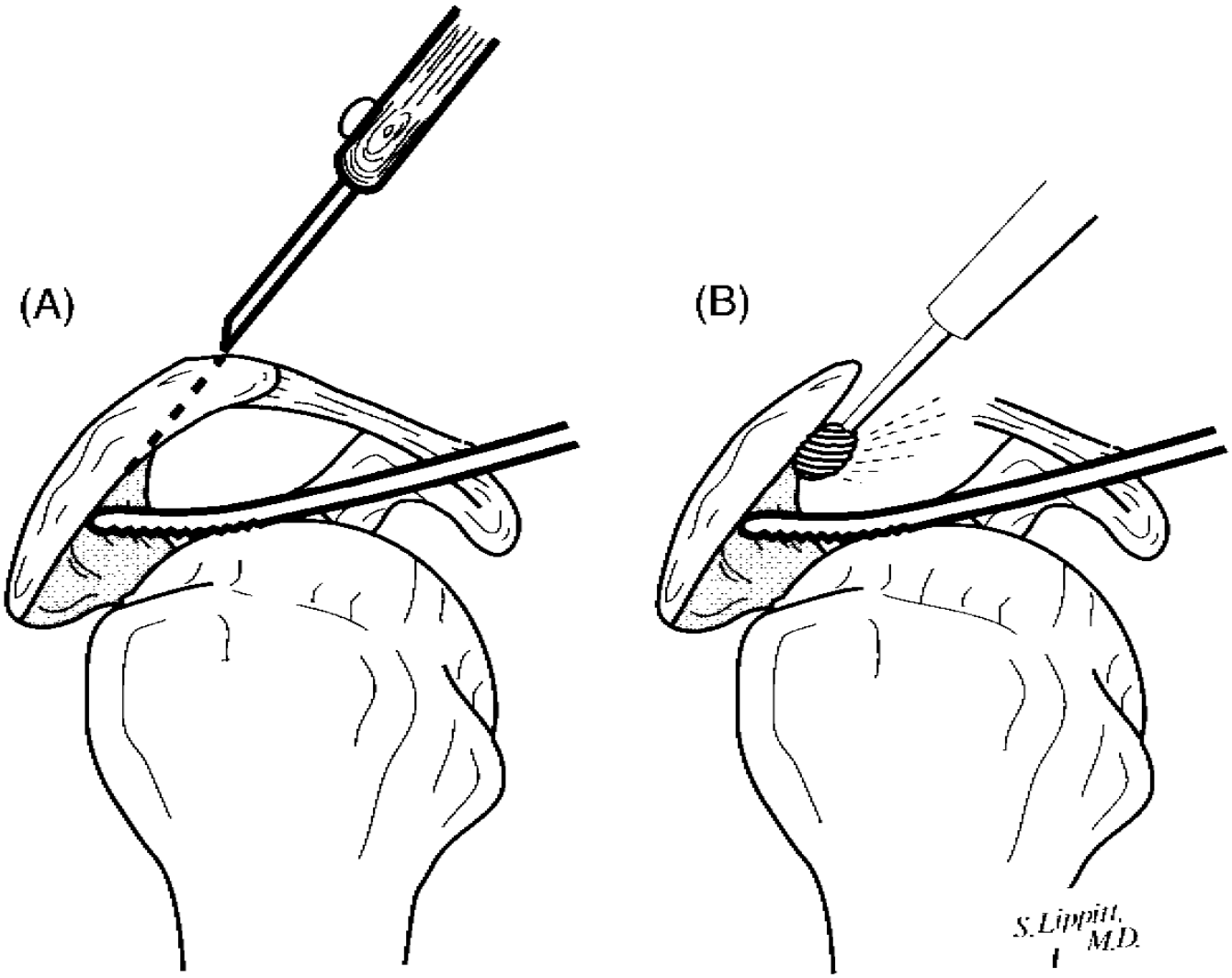
(A)
(B)
S.Lippitt, M.D.

1. For **rotator cuff tendinitis:**

The Hawkin's and Neer's tests alone may provide some value in ruling-in a rotator cuff tendinitis but is not specific to a specific tendon and may overlap with subacromial impingement test findings

The combination of a:

positive for both the Hawkins & Neer's tests is more valuable than *each test alone* for identifying rotator cuff tendinitis

Functional Impingement

Tape to Test

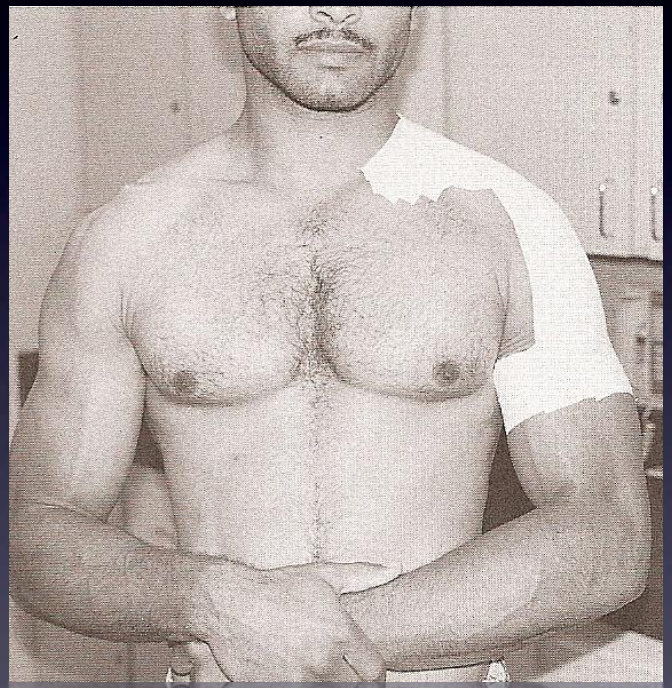

Position 1 - Arm at Side

- Observe for deformity
- Load and ShiftTesting
- Palpation for biceps and anterior capsule
- Yergason's - Biceps
- Resisted internal and external rotation
- Sulcus sign - Instability

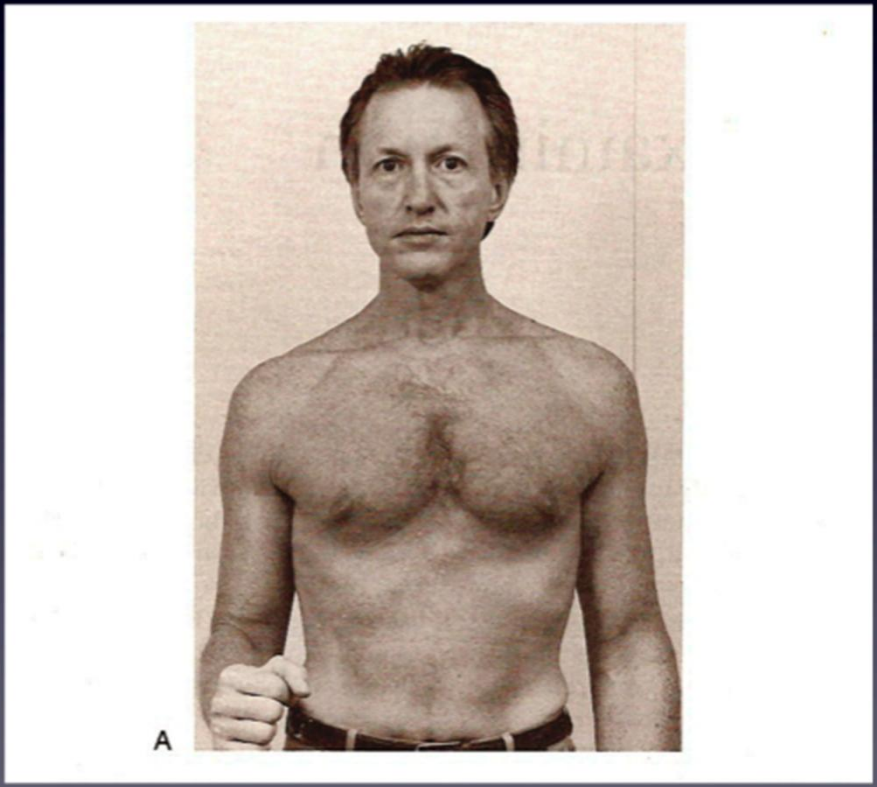

Position 2 - 90 Degrees Abduction

- Resisted internal and external rotation
- Passive internal/external rotation
- Resisted abduction
- With elbow extension

- Empty Can Test

Position 3 - 90 Degrees Elevation

- Palpation of teres minor/infraspinatus
- Passive internal rotation for anterior pain (Kennedy-Hawkin's); posterior pain = external rotator stretch
- With elbow extension and resistance, Speed's and Obrien's

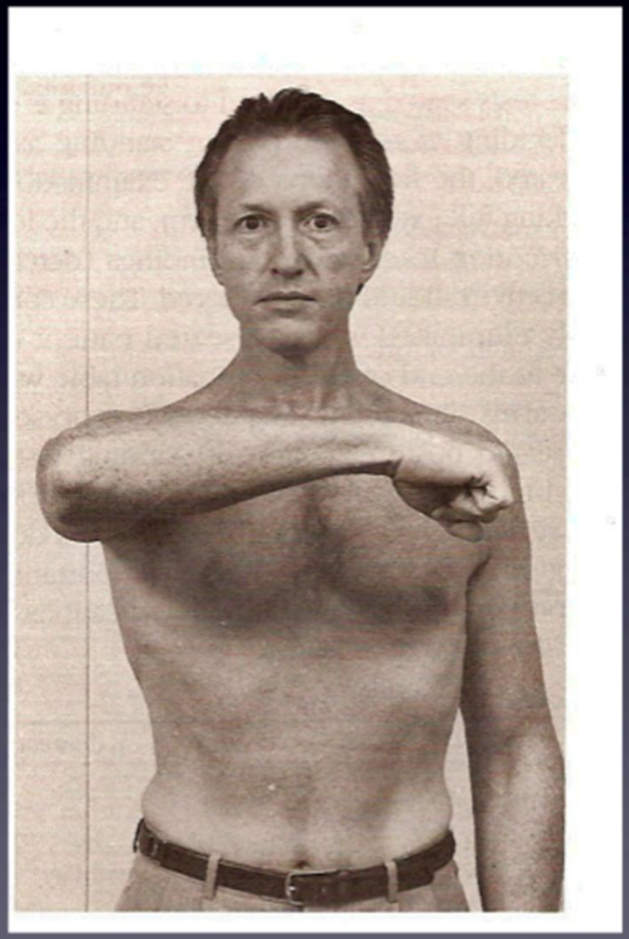

Position 4 - Arm Behind Back

- Palpation of supraspinatus
- Passive internal rotation
- Lift-Off Test - Subscapularis
- Internal Rotation lag Sign - Subscapularis
- Hand on hip - Anterior Slide Test (SLAP Lesion)